

# AMSER Rad Path

## Case of the Month July 2018



### Exophytic Gastric Mass

Anjali Singh OMS III , Lake Erie College of Osteopathic Medicine

Dr. Matthew Hartman, M.D. Allegheny Health Network

Dr. Kossivi Dantey, M.D. , Dr. Suzanne Schiffman, M.D. , Dr. Suzanne Morrissey ,M.D.

# Patient Presentation

50 year old male reported signs and symptoms of heartburn. He underwent an EGD which showed an extrinsic gastric mass. A CT was done to confirm this followed by an EUS during which biopsies were taken. The patient denied abdominal pain, nausea, emesis, fevers, chills, shortness of breath, change in bowel habits, weight loss or change in appetite

Past medical hx: GERD and hypertension

Surgical hx: Vasectomy

Family hx: melanoma and coronary artery disease in father, coronary artery disease in mother

Social hx: denies tobacco use and was never a smoker

Medications: chlorpheniramine, hydrochlorothiazide, lisinopril, pantoprazole, sucralfate

# Physical Exam

General Appearance: not any distress, awake, and oriented 3X

HEENT: pupils are equal and round, no evidence of scleral icterus

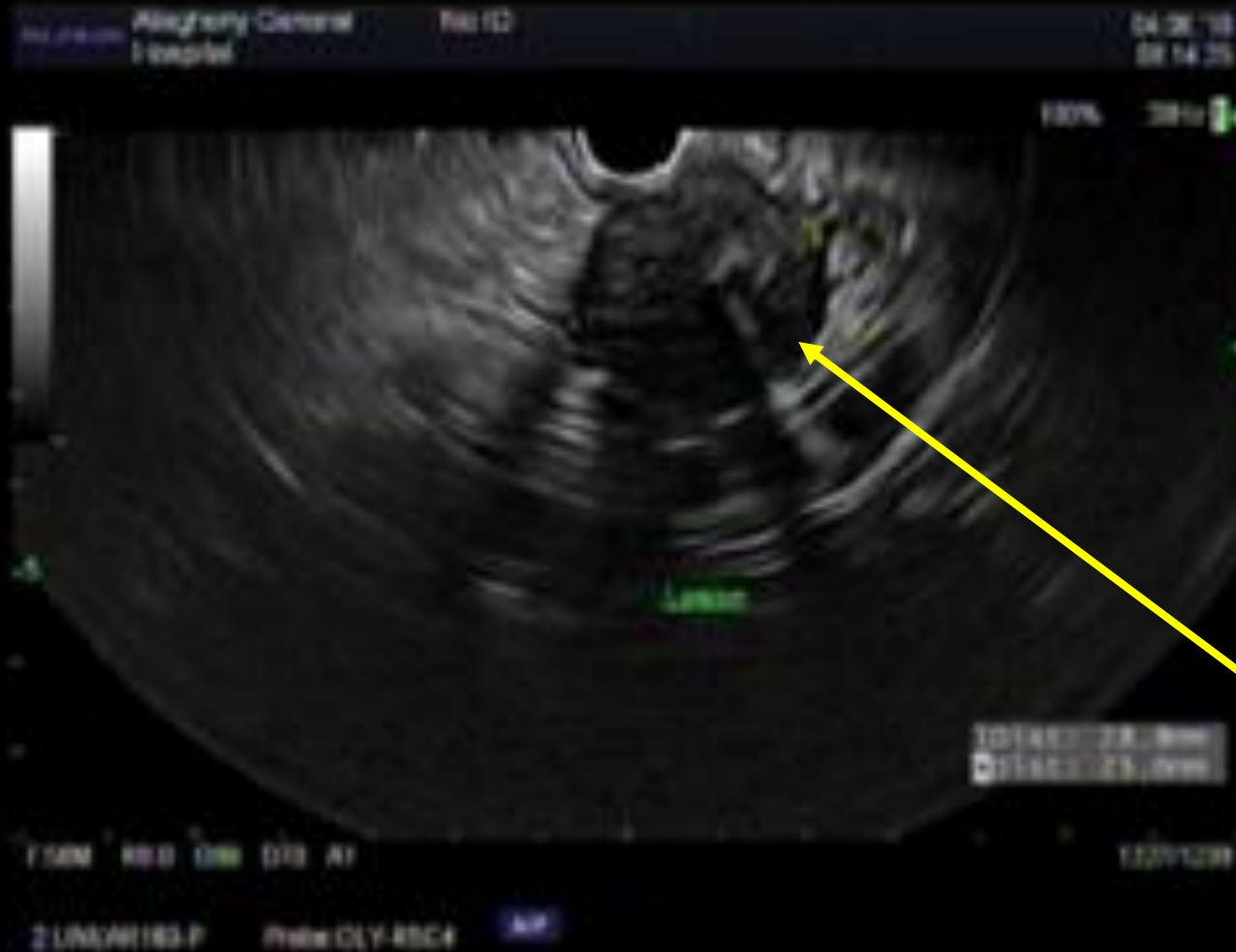Mouth: normal mucosa, no aphthous ulcers

Heart: normal S1, S2, no murmurs, rubs or gallops

Lungs : clear to auscultation bilaterally; no rhonchi or rales

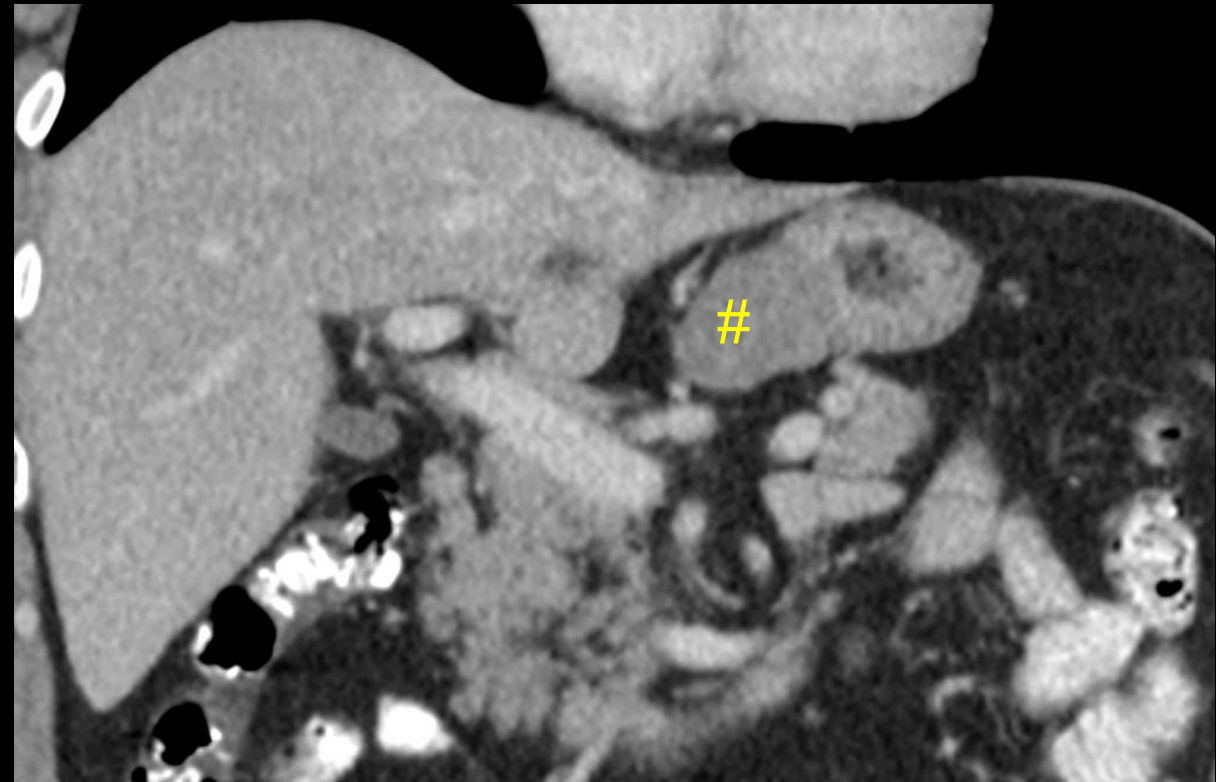
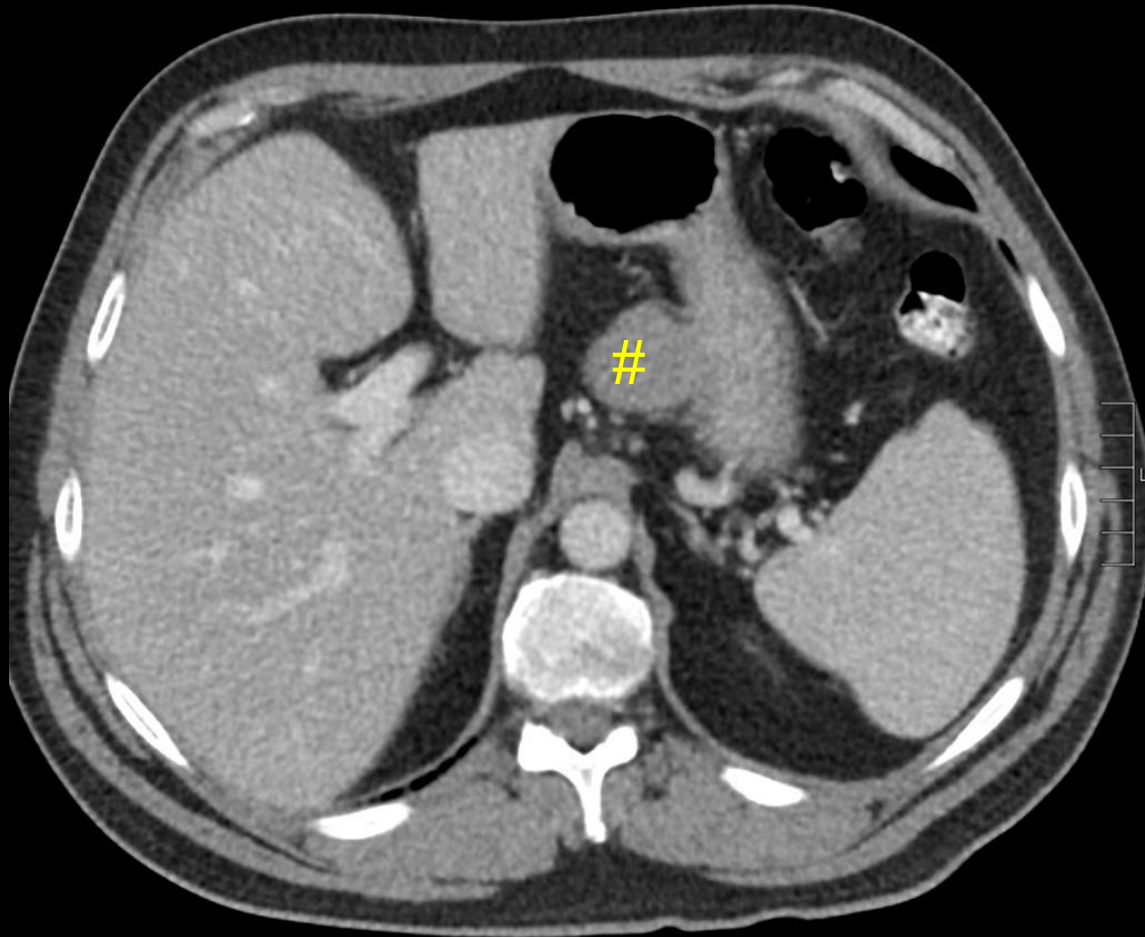
Abdomen: soft, nontender, nondistended, bowel sound are present, no hepatosplenomegaly, no rebound, no guarding

# EUS



- Hypoechoic, oval, intramural lesions in the lesser curve of the stomach.
- Appears to originate from the muscularis propria
- Measures 28 mm by 30 mm

# CT of Abdomen/ Pelvis with contrast



3.5 X 3.0 cm exophytic mass along the lesser curvature of the stomach

# Differential diagnosis based on imaging

Mesenchymal tumors of the GI wall

- Gastrointestinal Stromal Tumors (GISTs)
- Other mesenchymal tumor (schwannoma, leiomyoma)

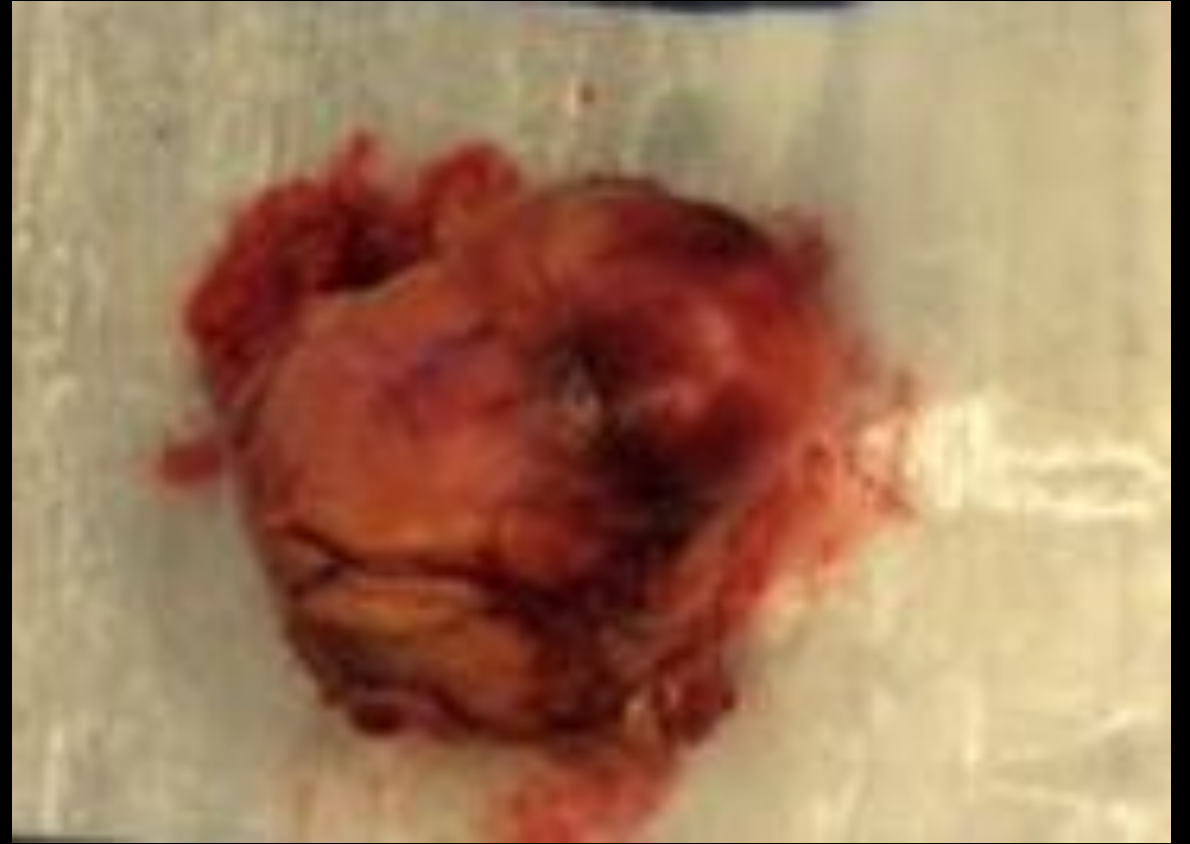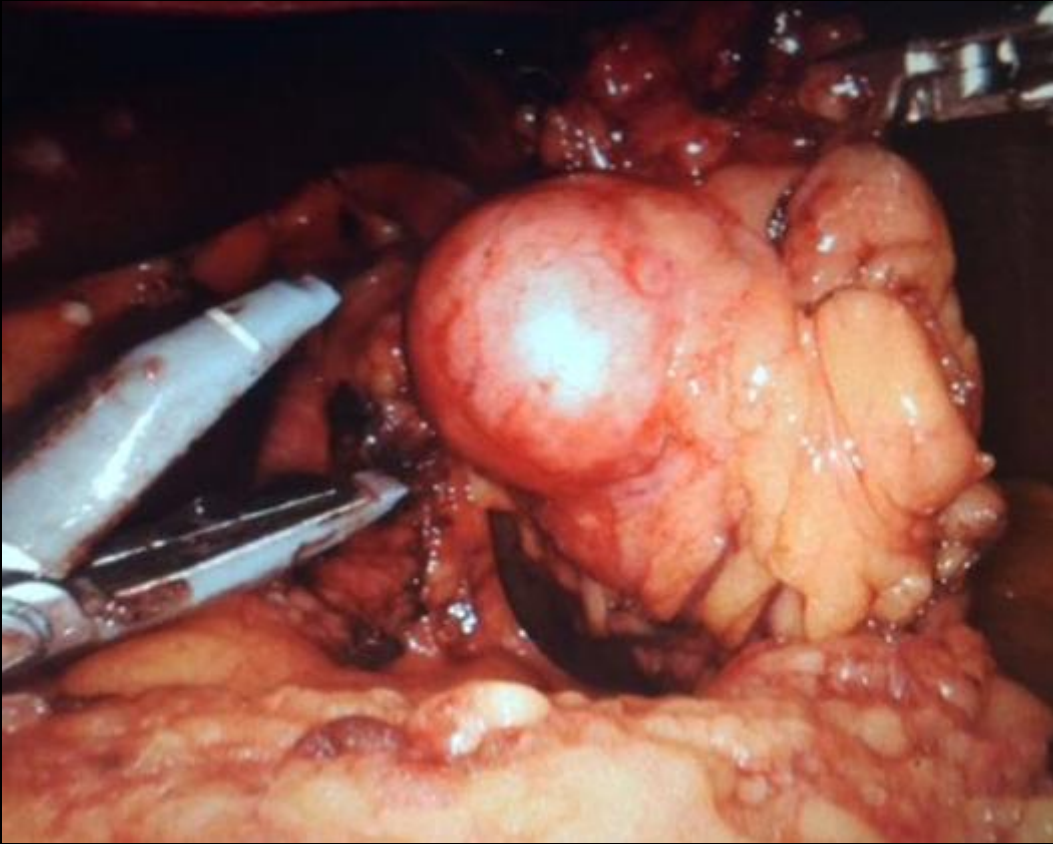
Gastric adenocarcinoma

Lymphoma

Metastasis

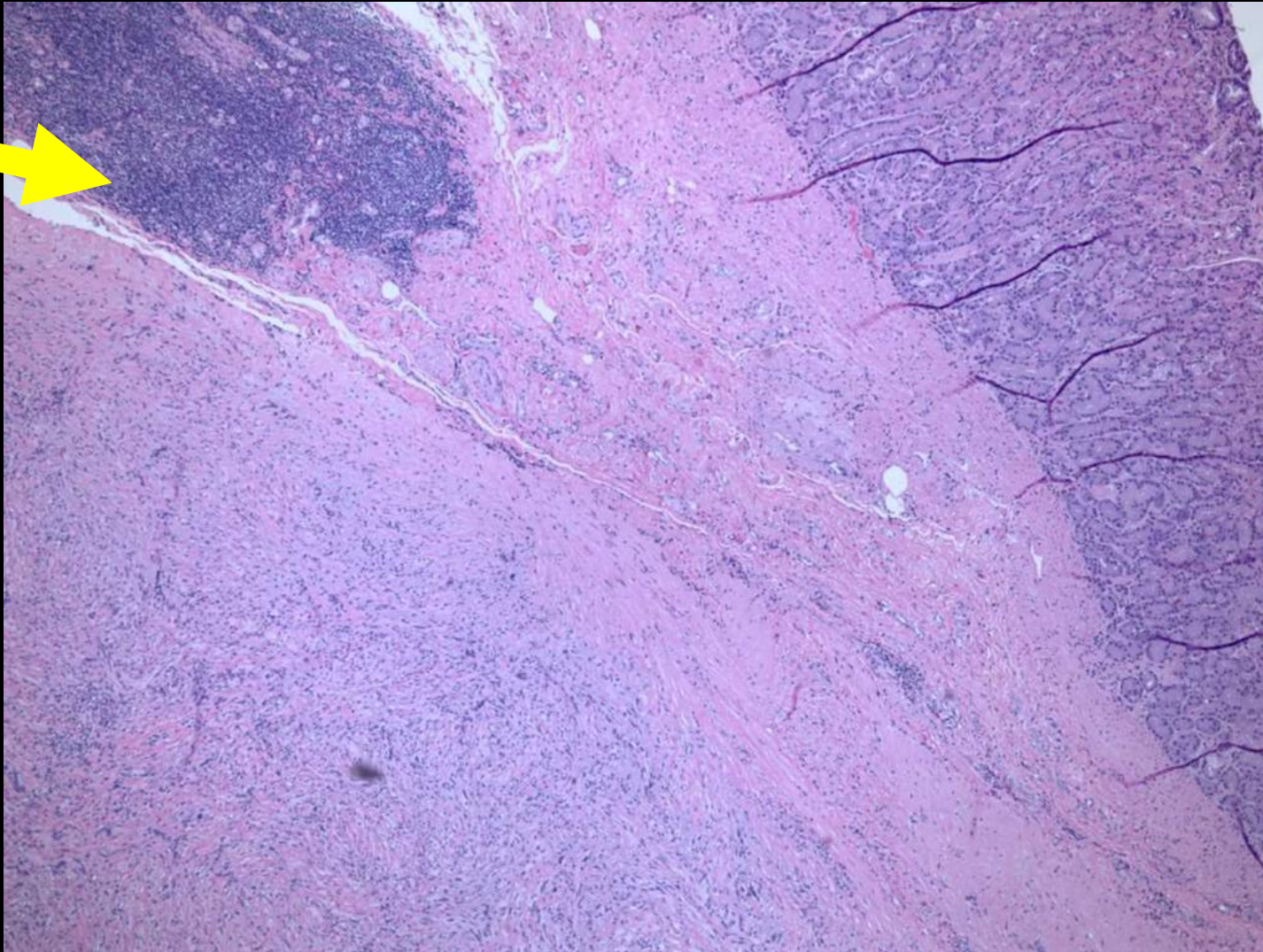


# Pathology from robotic assisted partial gastrectomy



4.2 X 3.2 X 2.5 cm tan, well circumscribed, firm lesion which adheres to gastric mucosa but does not invade into the mucosa

# Pathology

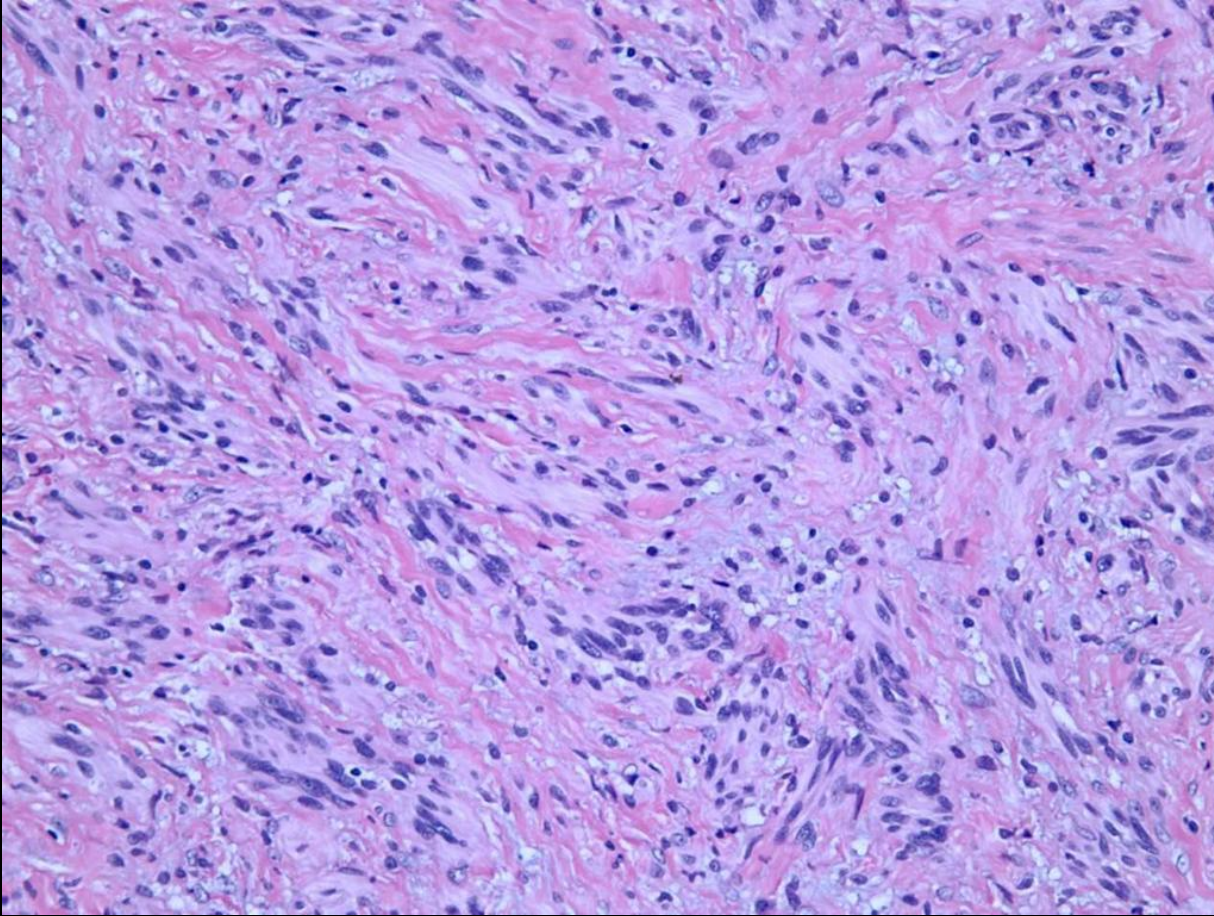


Well circumscribed tumor  
with a lymphoid cuff

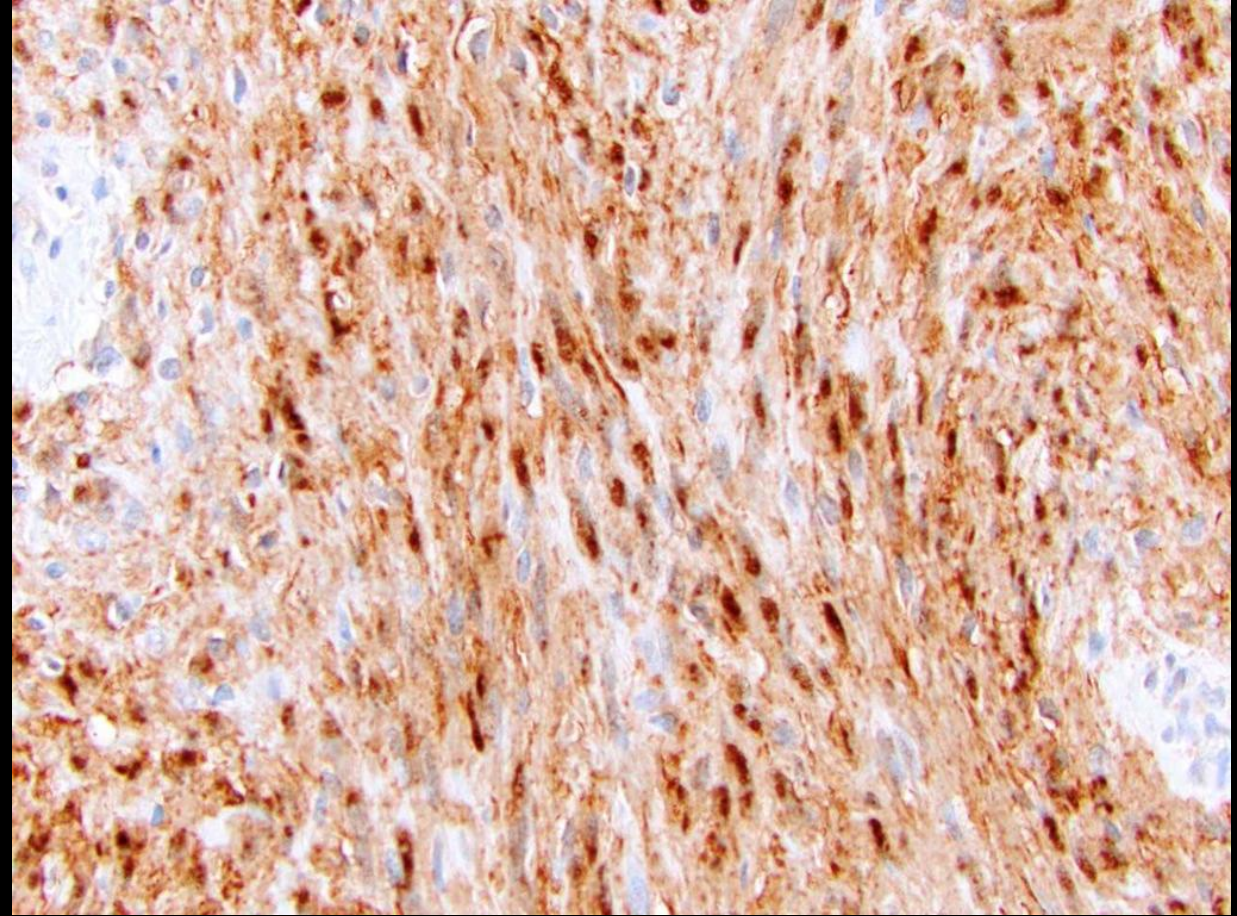
Low power H&E



High power



The tumor is composed of bland spindle cells.  
Mitotic figures, nuclear atypia and necrosis are absent



Immunohistochemistry is positive for S-100 protein  
and negative for CD117 and DOG-1

Final Dx:

Gastric Schwannoma

# Case Discussion

Gastric schwannoma are rare tumors that make up 0.2% of all gastric tumors

- Benign mesenchymal tumors
- Most common in 5th and 6th decades of females
- Submucosal exophytic gastric mass
- Stem from the schwann cells of the gut wall nerve plexus
- Asymptomatic and incidentally found



The clinical and radiologic presentation of gastric schwannomas is similar to that of the more common gastrointestinal stromal tumors( GISTs) which are also mesenchymal tumors but have 10-30% malignant tendency

GISTs make up 60-70% of gastric masses which results in the misdiagnosis of schwannomas until postoperative studies are completed

Diagnosis of a schwannoma is based on histologic and immunohistochemical markers

- Strong staining for S-100
- Negative for CD-117, DOG-1, CD-34 and smooth muscle actin

Tumor	S-100	Vimentin	GFAP	CD-117	DOG-1	CD-34
Schwannoma	+	+	+	-	-	-
GIST	-	-	-	+	+	+/-

(Shah 2015)



# References:

Atmatzidis S, Chatzimavroudis G, Dragoumis D, Tsiaousis P, Patsas A, Atmatzidis K. Gastric schwannoma: a case report and literature review. Hippokratia. 2012;16(3):280-282.

Shah AS, Rathi PM, Somani VS, Mulani AM. Gastric Schwannoma: A Benign Tumor Often Misdiagnosed as Gastrointestinal Stromal Tumor. Clinics and Practice. 2015;5(3):775. doi:10.4081/cp.2015.775.

Yoon W, Paulson K, Mazzara P, Nagori S, Barawi M, Berri R. Gastric schwannoma: a rare but important differential diagnosis of a gastric submucosal mass. Case Rep Surg. 2012;2012:28098