

# AMSER Case of the Month

## March 2021

16 month old female presents with limp and refusal to bear weight on right leg for 7 days

Olivier F. Noel, MS4

Penn State College of Medicine

Michael O'Bryant, DO

Penn State College of Medicine

James M. Brian, MD

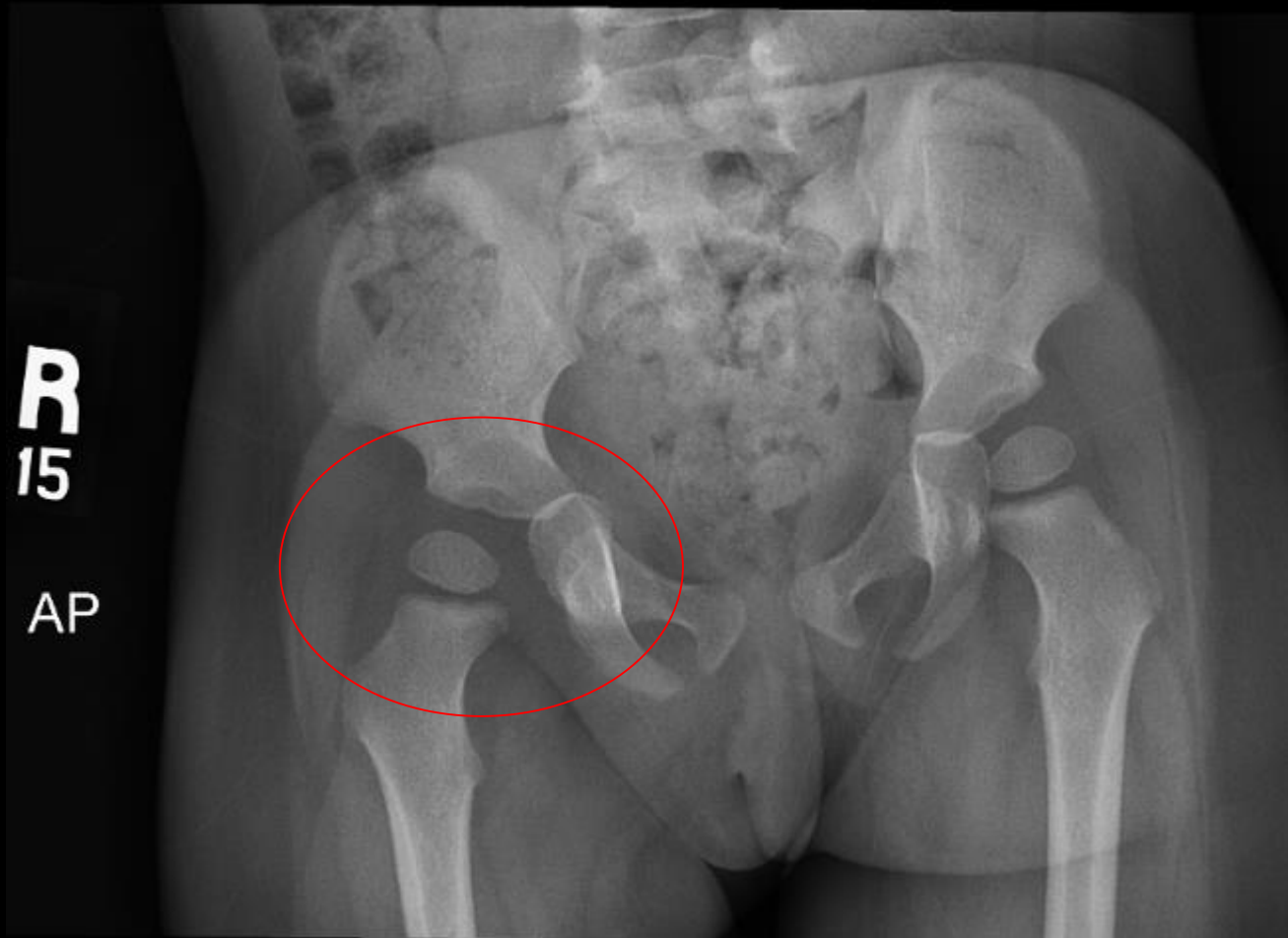
Penn State College of Medicine



# Clinical History

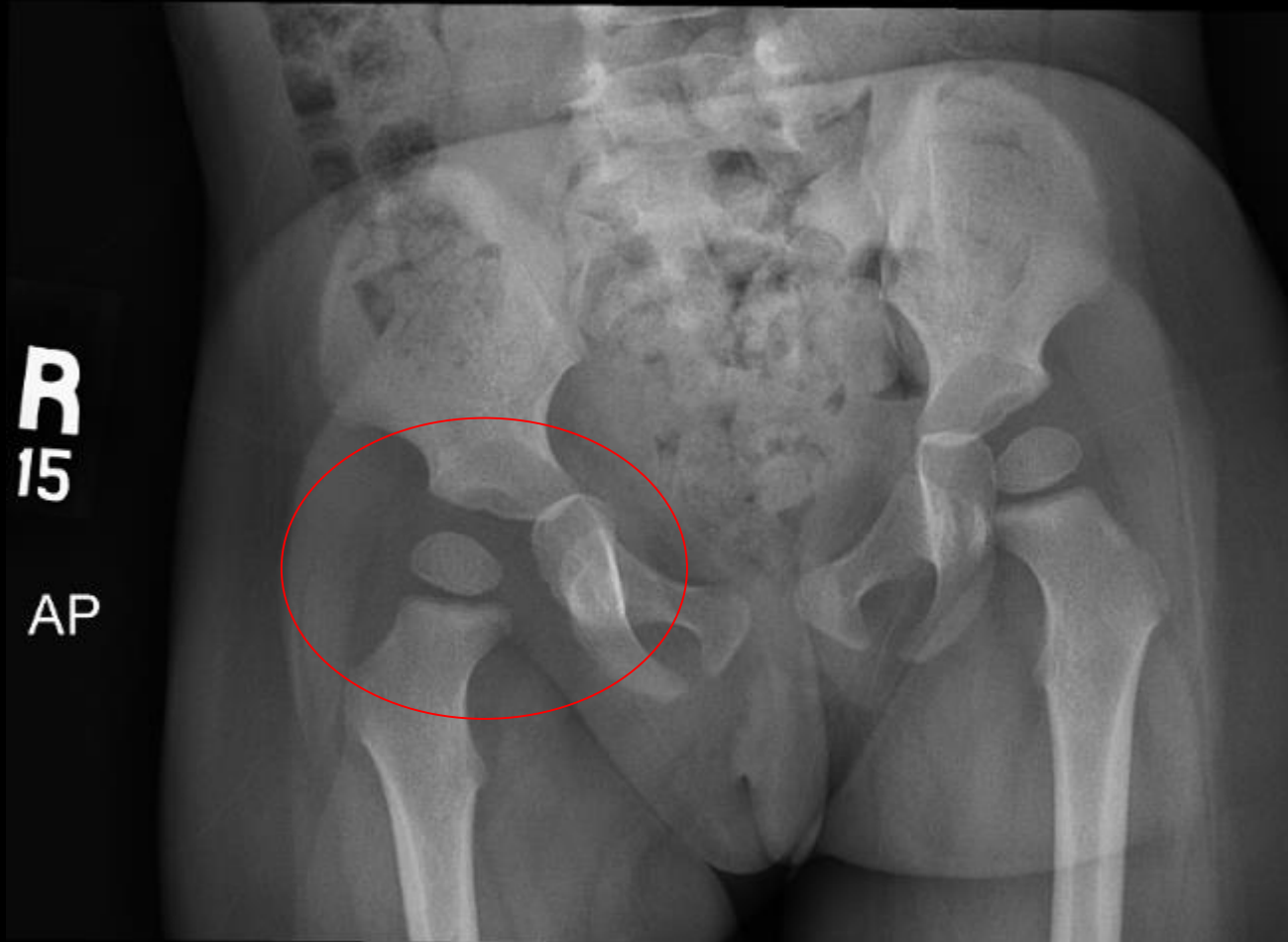
- 16 month old female presents with limp and refusal to bear weight on right leg for 7 days.
  - Patient had low-grade fever with decreased appetite 1 day prior to onset of limp, diagnosed with ear infection by pediatrician and started on antibiotics.
  - Continues to crawl, but refuses to stand or walk.
- Repeat visit to pediatrician led to diagnosis of transient synovitis.
  - Ibuprofen not alleviating symptoms.
  - No history of trauma or tick bites.
  - Hip/pelvis radiograph ordered.
- Referred to orthopedics for further evaluation.

# Findings (unlabeled)



Ordered by pediatrician

# Findings (labeled)



X-ray showing widening of the right hip joint space with mild subluxation of the hip.

# Clinical History

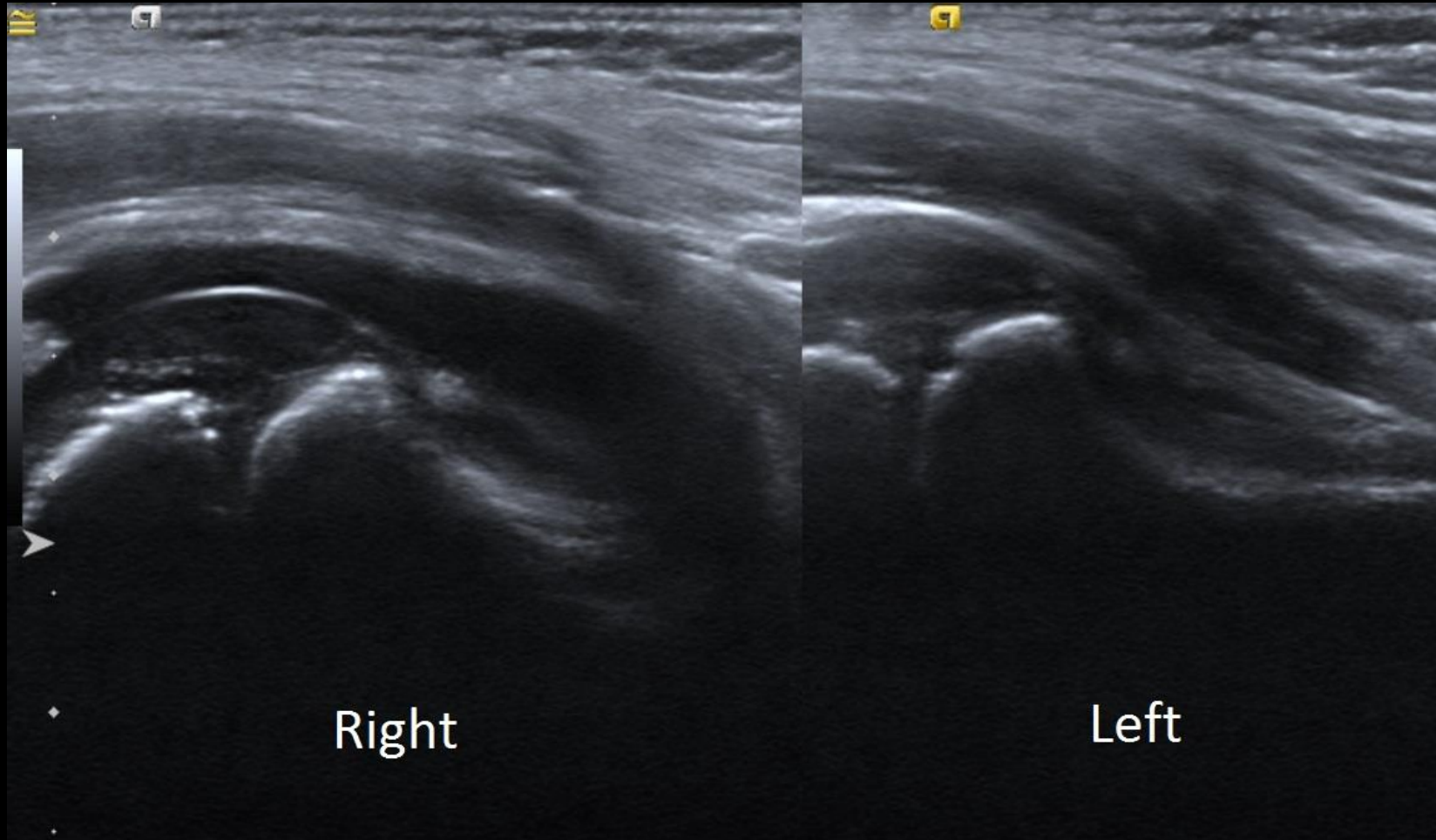
## Physical Exam by orthopedics:

- Afebrile
- General: nontoxic, well-appearing, generally fussy
- Musculoskeletal:
  - normal passive range of motion of hips, knees, ankles
  - no tenderness to palpation of lower extremities
  - fussy during manipulation of the hips but does not exhibit signs of pain with hip movement
- Gait: refuses to bear weight on right leg, will not walk

# Pertinent Labs

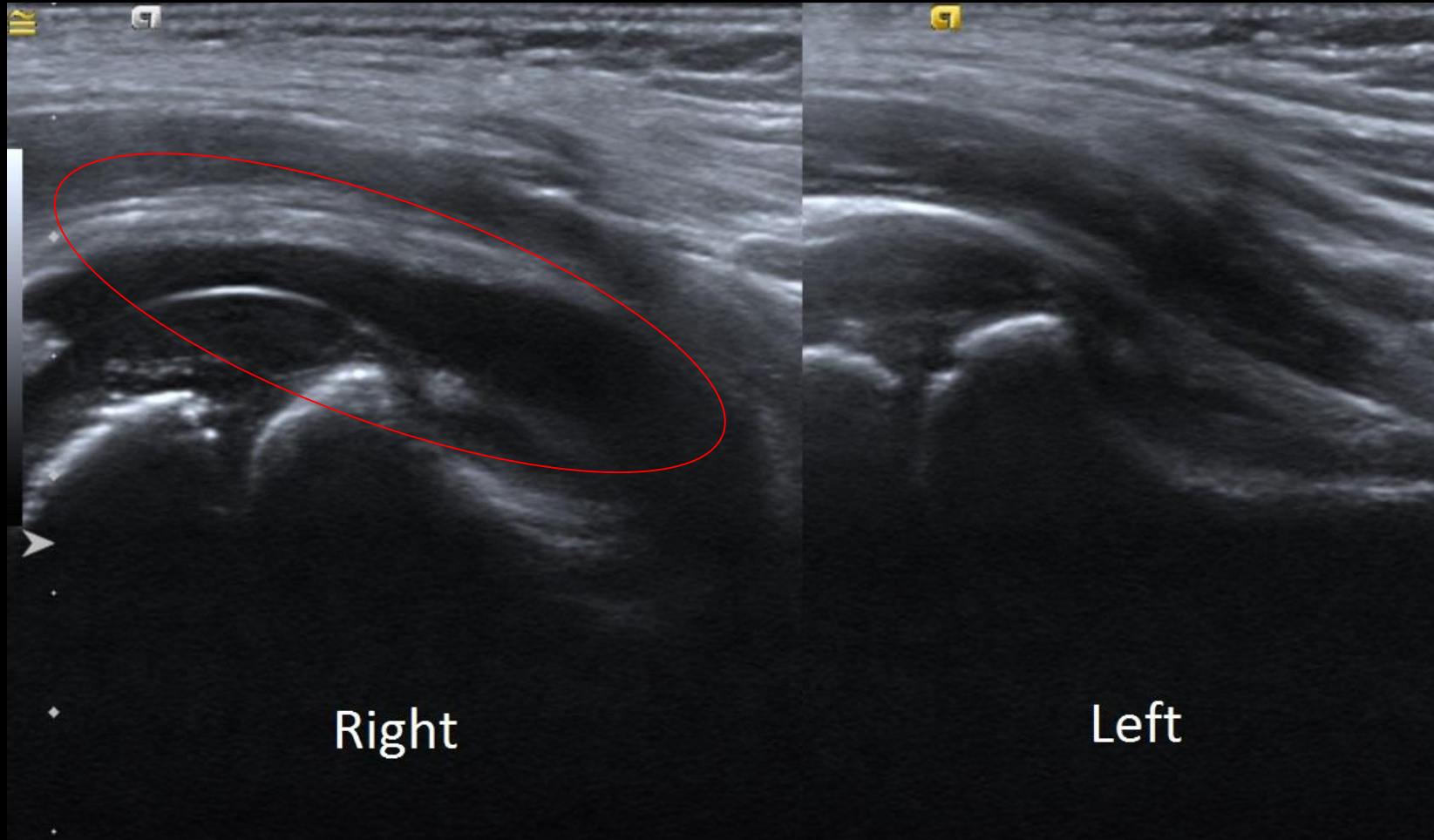
- Initial labs (at pediatrician's office):
  - ESR 50 mm/h
  - CRP 2.76 mg/L
  - WBC 8.0
  - platelets 350K
  - blood cultures showed no growth after 72 hours
- Repeat labs (3 days later):
  - ESR 58
  - CRP 5.73
  - WBC 12.6
  - platelets 616K
  - Ultrasound (ordered by orthopedics) showed right hip effusion

# Findings (unlabeled)



Ordered by orthopedics  
after referral

# Findings (labeled)



Ultrasound comparison of right and left hips, with large right hip joint effusion seen.

With elevated inflammatory markers, patient was sent to ED for right hip aspiration where 5.5 cc yellow non-purulent joint fluid was aspirated by radiology.



What Imaging Should We Order?

# Select the applicable ACR Appropriateness Criteria

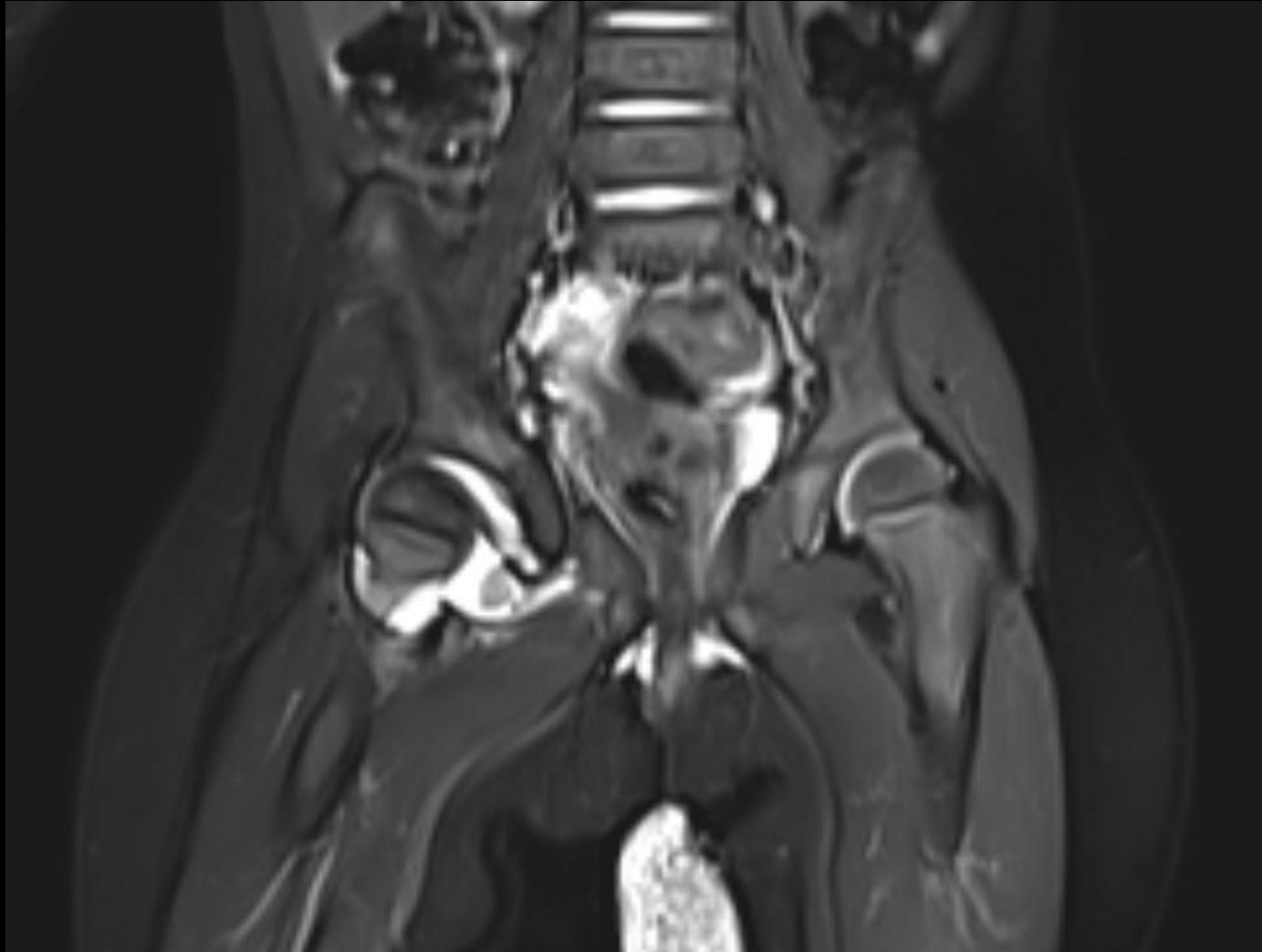**Variant 4:** Child up to age 5. Acute limp. Symptoms localized to the hip. Concern for infection. Initial imaging.

Procedure	Appropriateness Category	Relative Radiation Level
US hips	Usually Appropriate	0
MRI pelvis without and with IV contrast	Usually Appropriate	0
MRI pelvis without IV contrast	Usually Appropriate	0
3-phase bone scan pelvis and lower extremity	May Be Appropriate	⊗⊗⊗⊗
Radiography pelvis	May Be Appropriate	⊗⊗
Radiography lumbar spine	Usually Not Appropriate	⊗⊗
CT pelvis with IV contrast	Usually Not Appropriate	⊗⊗⊗⊗
CT pelvis without and with IV contrast	Usually Not Appropriate	⊗⊗⊗⊗
CT pelvis without IV contrast	Usually Not Appropriate	⊗⊗⊗⊗

This imaging modality was ordered by orthopedics

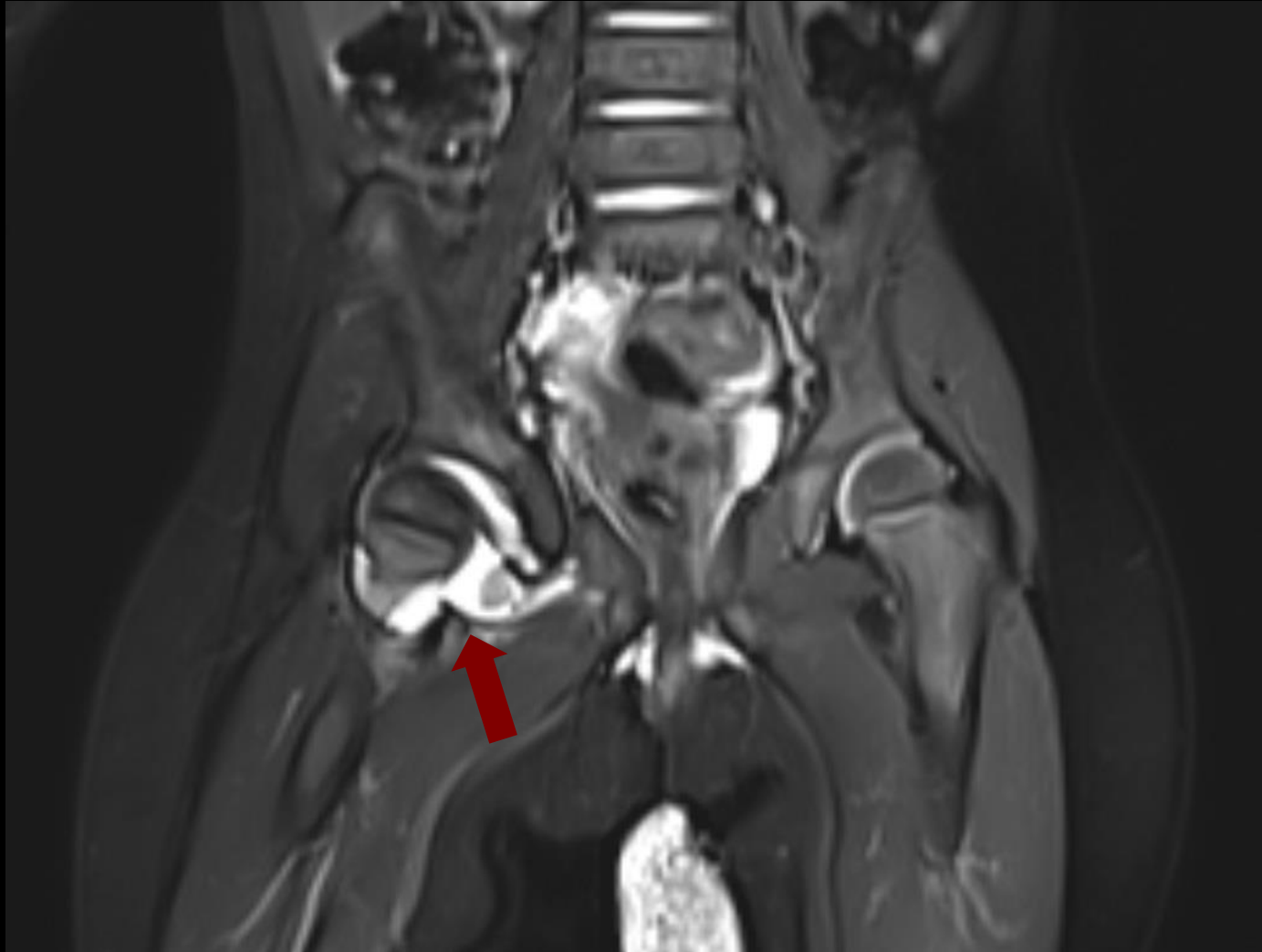

# Findings (unlabeled)

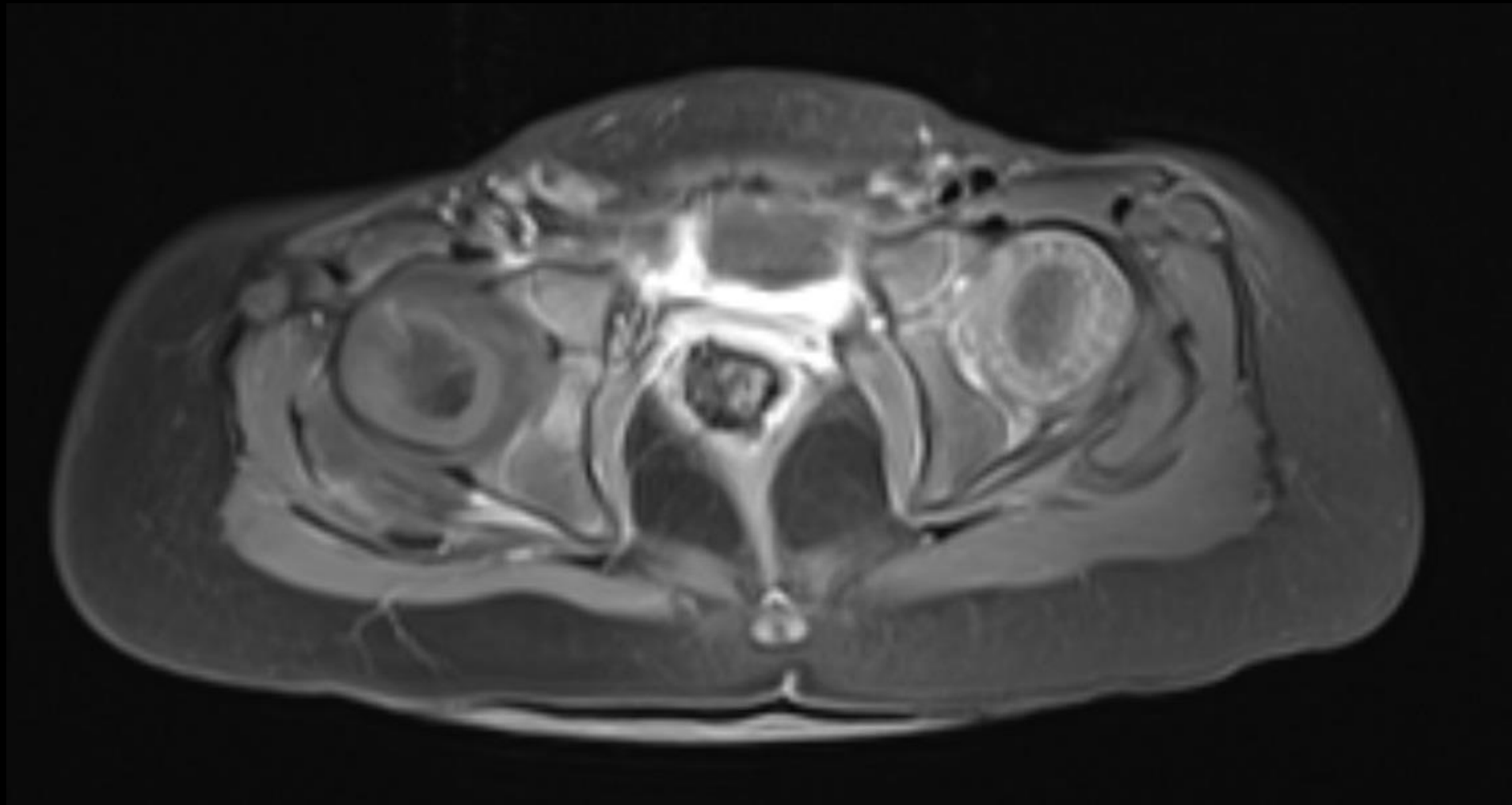


# Findings: (labeled)

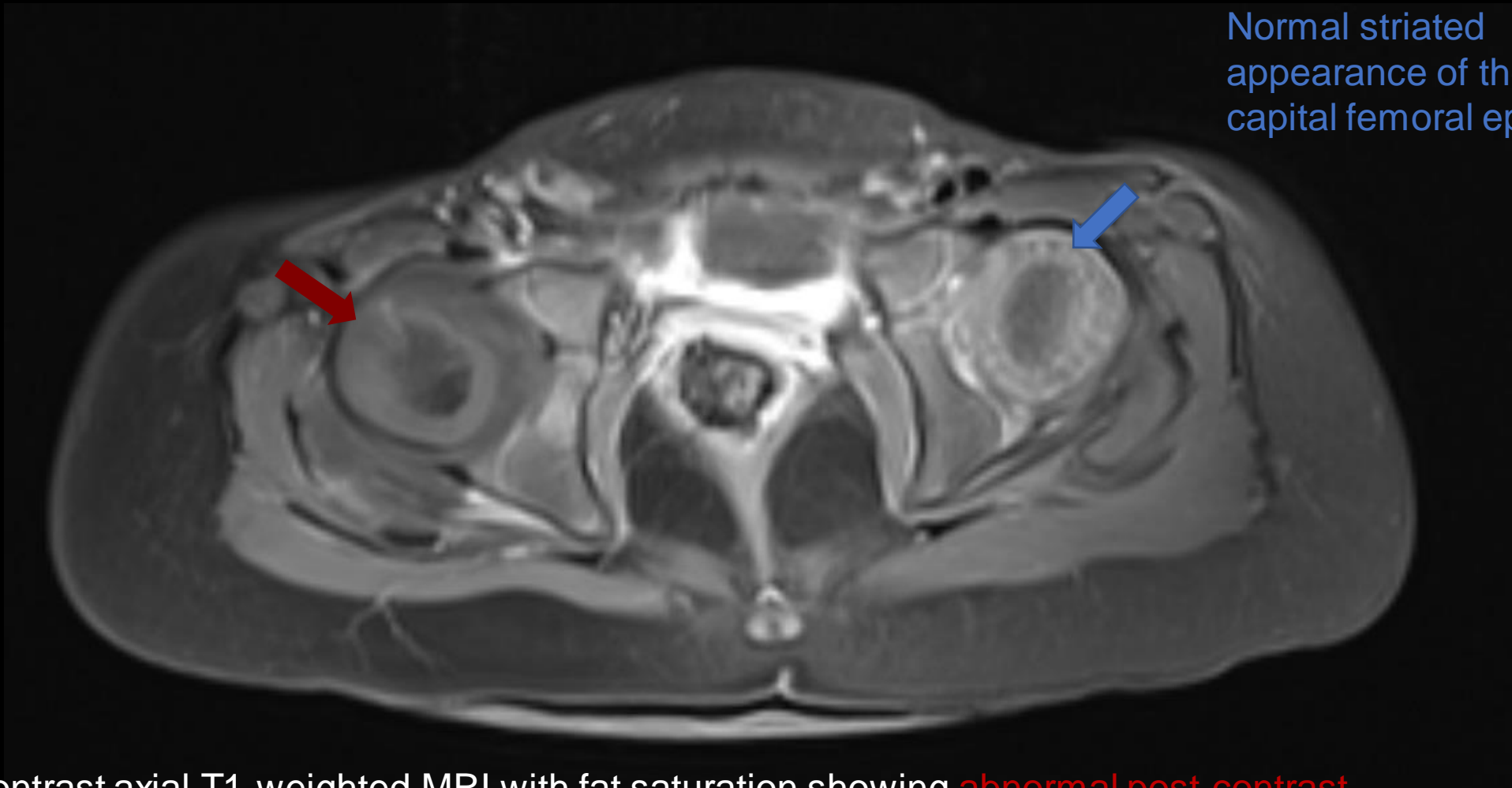
Coronal T2-weighted MRI with fat saturation confirming right hip joint effusion.



# Findings (unlabeled)



# Findings: (labeled)



Normal striated appearance of the left capital femoral epiphysis.

Post-contrast axial T1-weighted MRI with fat saturation showing **abnormal post-contrast signal of the right capital femoral epiphysis with a lack of the normal striated appearance.** These changes are due to decreased perfusion of the epiphysis.

Final Dx:

Septic arthritis

# Pediatric septic arthritis

- Overall incidence estimated to be 4 to 10 per 100,000 children in developed countries.
- Most commonly affected joints are in the lower extremities with knees, hips, and ankles accounting for up to 80% of cases.
- Requires urgent recognition and treatment to avoid joint destruction.
- Most common responsible pathogen in pediatric cases is *Staphylococcus aureus*.



# Pediatric septic arthritis

- Imaging of the affected joint should start with plain radiographs. Ultrasound is a rapid, noninvasive method to help detect joint effusion. MRI is a helpful clinical tool for diagnosis and revealing extent of infection.
- Treatment course involves surgical debridement and intravenous antibiotics followed by transition to oral antibiotics when clinically appropriate.
- Surgical treatment consists of open arthrotomy with joint decompression and irrigation and debridement.
- On the morning after presentation to the emergency room, this patient underwent surgical debridement and irrigation of the hip, revealing purulent fluid in the joint space. She was treated with antibiotics and recovered.

# References:

- Arnold JC, Bradley JS. Osteoarticular infections in children. *Infect Dis Clin North Am* 2015;29(3): 557–74.
- Baitch A. Recent observations of acute suppurative arthritis. *Clin Orthop* 1962;22:157–66.
- Laine JC, Denning JR, Riccio AI, et al. The use of ultrasound in the management of septic arthritis of the hip. *J Pediatr Orthop B* 2015;24(2):95–8
- Mazur JM, Ross G, Cummings J, et al. Usefulness of magnetic resonance imaging for the diagnosis of acute musculoskeletal infections in children. *J Pediatr Orthop* 1995;15(2):144–7.
- Kwack KS, Cho JH, Lee JH, Cho JH, Oh KK, Kim SY. Septic arthritis versus transient synovitis of the hip: gadolinium-enhanced MRI finding of decreased perfusion at the femoral epiphysis. *AJR Am J Roentgenol.* 2007 Aug;189(2):437-45.
- Kocher MS, Mandiga R, Murphy JM, et al. A clinical practice guideline for treatment of septic arthritis in children: efficacy in improving process of care and effect on outcome of septic arthritis of the hip. *J Bone Joint Surg Am* 2003;85-A(6): 994–9.