

AMSER Case of the Month

January 2021

Change in Breast Density

Lauren Finch CMSRU

Pauline Germaine, DO

Cooper University Hospital



Patient Presentation

Patient is currently a 46 yo with PMHx of invasive ductal carcinoma of the right breast s/p right mastectomy with sentinel lymph node biopsy in 2007 who presents for routine scheduled annual evaluation of the left breast

Disease History/Course:

- Pathology: 1.8cm invasive ductal carcinoma. Lymph node 0.9cm. Comedo-type DCIS. Micrometastasis in 1 lymph node
- ER positive, PR weekly positive, HER-2/neu positive
- S/p adjuvant Adriamycin/Cytoxan, followed by Taxol, s/p 1 year Herceptin. Treatment with Tamoxifen from 2009 – 2019 & Lupron 2009-2013

What Imaging Should We Order?

- Routine Annual Mammography
- Diagnostic Mammogram as needed for palpable masses and/or pain
- Ultrasound as needed for screening in the setting of dense breast tissue, areas of concern and/or palpable masses and/or pain

Select the applicable ACR Appropriateness Criteria

Variant 2:

Breast cancer screening. Intermediate-risk women: women with personal history of breast cancer, lobular neoplasia, atypical ductal hyperplasia, or 15% to 20% lifetime risk of breast cancer.

Procedure	Appropriateness Category	Relative Radiation Level
Mammography screening	Usually Appropriate	☼☼
Digital breast tomosynthesis screening	Usually Appropriate	☼☼
MRI breast without and with IV contrast	May Be Appropriate	○
US breast	May Be Appropriate	○
FDG-PET breast dedicated	Usually Not Appropriate	☼☼☼☼
Sestamibi MBI	Usually Not Appropriate	☼☼☼
MRI breast without IV contrast	Usually Not Appropriate	○

These imaging modalities were ordered by the patients oncologist



This patient falls under variant 2, given her personal history of breast cancer without BRCA genetic mutation

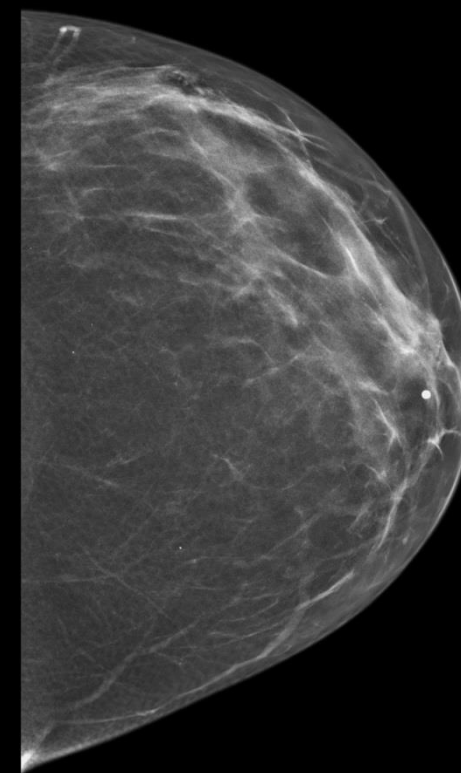
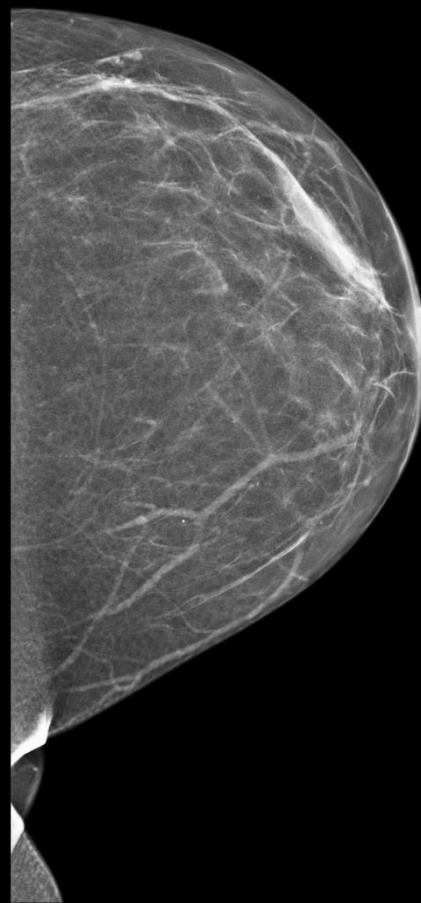
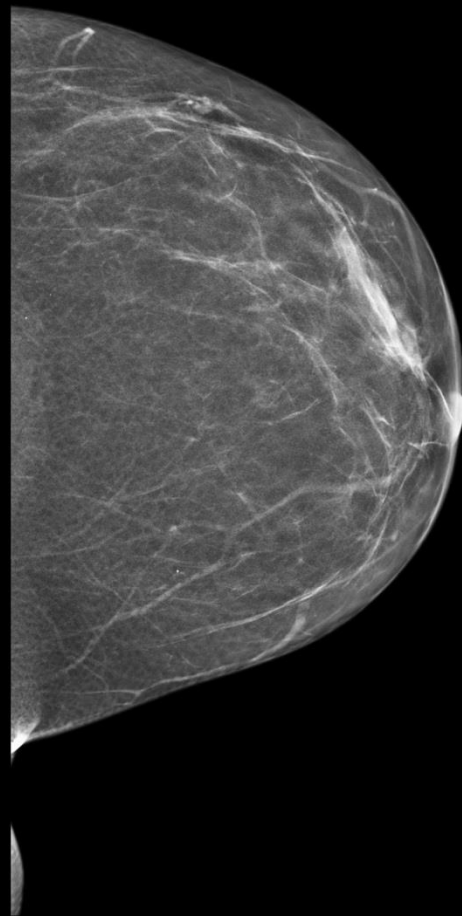
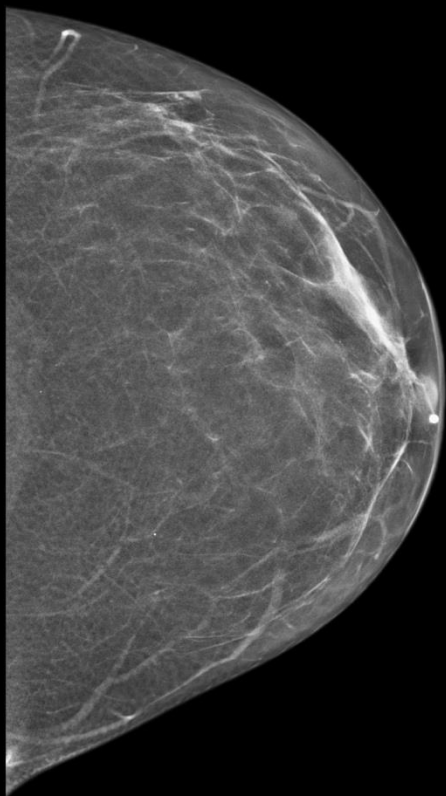
Annual mammograms

2017

2018

2019

2020



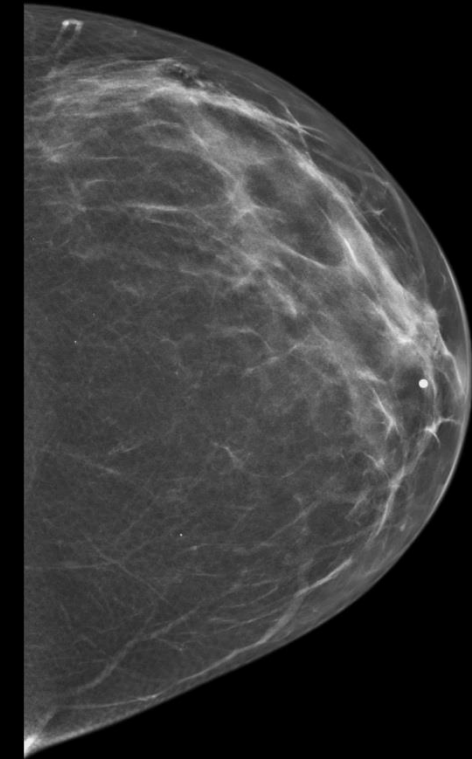
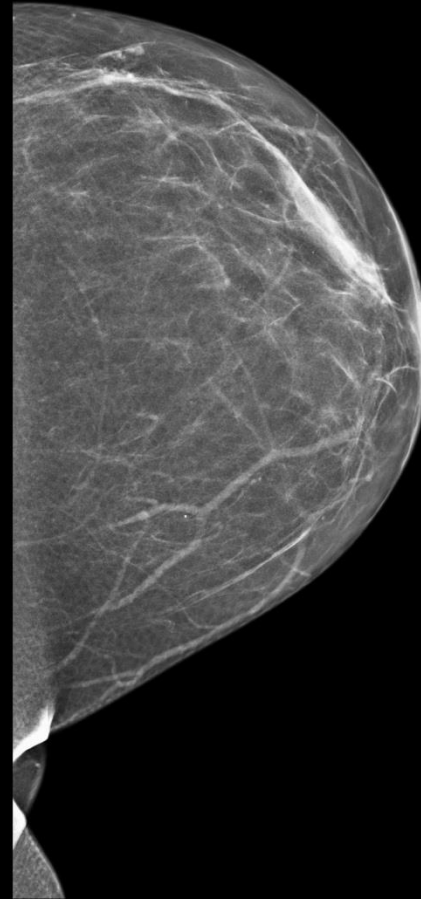
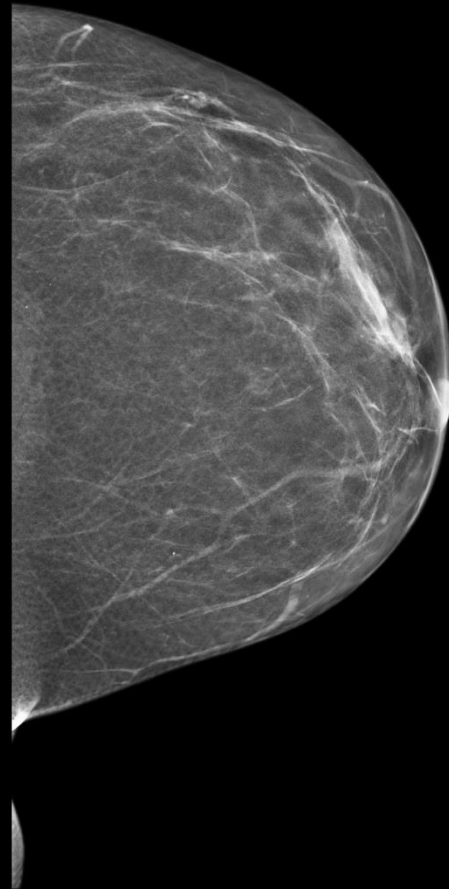
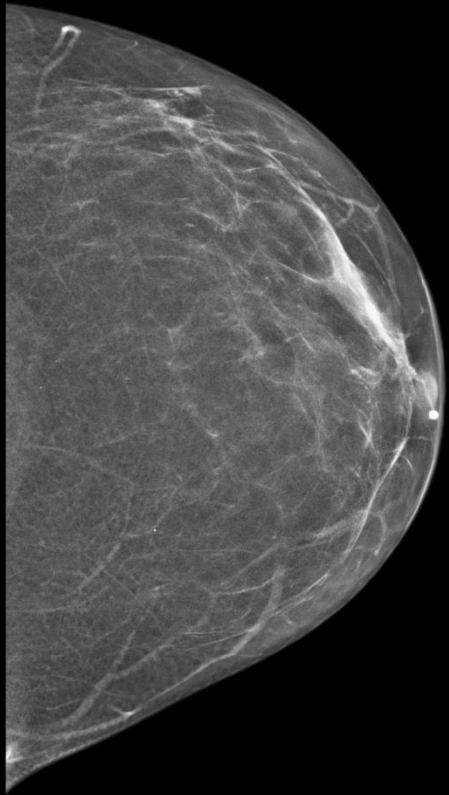
Annual mammograms -Density Levels

2017: Scattered

2018: Scattered

2019: Scattered

2020: Heterogeneously
Dense



Final Dx:

Increasing Breast Density after the cessation of chronic
Tamoxifen use

Discussion

- Women with progesterone and estrogen receptor positive breast cancer, adjuvant endocrine therapy is indicated
 - Shown to improve the rates of recurrence, second breast cancers, and survival
- Tamoxifen is a selective estrogen receptor modulator
 - Works as an antagonist on the estrogen receptors in the breast
 - Adjuvant endocrine therapy of choice in premenopausal women (our patient)
 - Used in postmenopausal women with a contraindication to aromatase inhibitors

Discussion

- Complications of Tamoxifen therapy include osteoporosis, endometrial adenocarcinoma, uterine sarcoma, stroke, pulmonary embolism
- Tamoxifen can have an impact on breast density. Due to its antagonist effects on estrogen in the breast and the idea that estrogen can increase density in breast tissue (as seen in premenopausal women and women on HRT), tamoxifen use can reduce breast density from baseline
- There are some studies that show an increase in breast density after the cessation of tamoxifen (as shown in our patient case)
 - One study showed 48% of patients saw an increase in breast density after the cessation of tamoxifen treatment

References:

- <https://acsearch.acr.org/docs/70910/Narrative/>
- https://www.uptodate.com/contents/adjuvant-endocrine-therapy-for-postmenopausal-women-with-hormone-receptor-positive-breast-cancer?search=tamoxifen%20breast%20cancer&source=search_result&selectedTitle=1~150&usage_type=default&display_rank=1#H631834246
- https://www.uptodate.com/contents/adjuvant-endocrine-therapy-for-premenopausal-women-with-hormone-receptor-positive-breast-cancer?sectionName=LOW-TO-AVERAGE-RISK,%20HORMONE%20RECEPTOR-POSITIVE%20CANCERS&search=tamoxifen%20breast%20cancer&topicRef=749&anchor=H1508165867&source=see_link#H2580928607
- [https://www.clinicalimaging.org/article/S0899-7071\(01\)00329-1/fulltext](https://www.clinicalimaging.org/article/S0899-7071(01)00329-1/fulltext)
- Chen JH, Chang YC, Chang D, et al. Reduction of breast density following tamoxifen treatment evaluated by 3-D MRI: preliminary study. *Magn Reson Imaging*. 2011;29(1):91-98. doi:10.1016/j.mri.2010.07.009
- Chow CK, Venzon D, Jones EC, Premkumar A, O'Shaughnessy J, Zujewski J. Effect of tamoxifen on mammographic density. *Cancer Epidemiol Biomarkers Prev*. 2000 Sep;9(9):917-21. PMID: 11008909.