

AMSER Case of the Month: April 2023

69 y.o. female presenting with LUQ pain and dysphagia

Raymond A. Crowthers IV, OMS-1

Rowan-Virtua School of Osteopathic Medicine

Frank Santisi MD, PGY 2

Mark T. DiMarcangelo DO, MSc, FACR, FAOCR

Cooper University Hospital

Patient Presentation

- **HPI:** 69 y.o. female presenting with LUQ pain, nausea, and bloating. She complains of dysphagia and painful emesis but denies odynophagia. Smaller, more frequent meals have helped minimally.
- **PMH:** gastroesophageal reflux disease (GERD) and 1cm hiatal hernia diagnosed on EGD in 2014, previous esophageal diverticulum repair in 2006
- **Meds:** Pantoprazole 40mg daily
- **Allergies:** NKDA
- **Vitals:** BP 122/78, Pulse 74, SpO2 98%, Weight 158 lbs, Height 5'6"
- **Physical Exam:** No acute distress and no scleral icterus. Abdomen is soft, nontender and without distension or herniation. Bowel sounds are normal. Normal pulmonary effort and breath sounds.

Pertinent Labs

- Alkaline Phosphate: 65 IU/L
- AST: 17 IU/L
- ALT: 13 IU/L
- Glucose: 102 mg/dL
- Sodium: 141 mmol/L
- Potassium: 4.8 mmol/L
- Chloride: 104 mmol/L
- WBC: $11.2 \times 10^3/\mu\text{L}$
- Hemoglobin: 16.0 g/dL

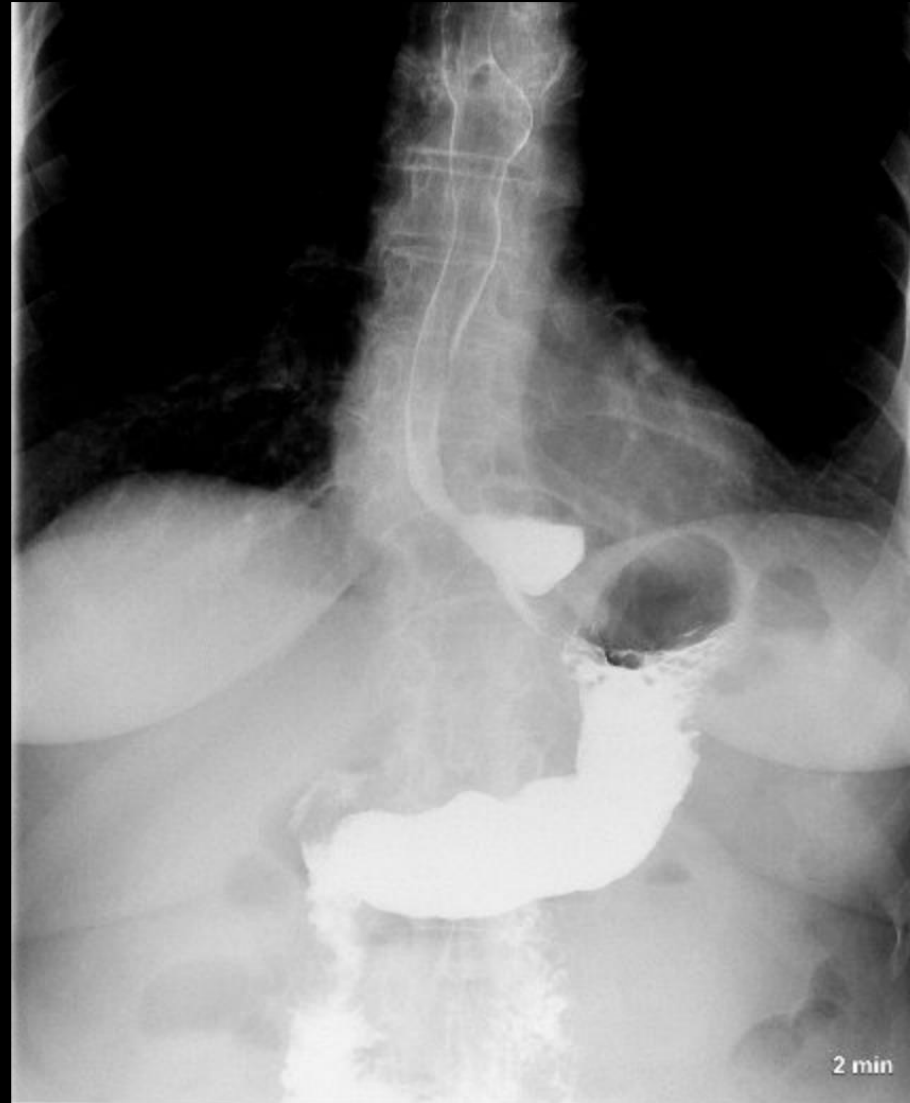
What Imaging Should We Order?

Select the applicable ACR Appropriateness Criteria

Fluoroscopy biphasic esophagram	1-10 mSv ☠☠☠	Not Assigned	Usually appropriate	●
Fluoroscopy barium swallow modified	1-10 mSv ☠☠☠	Not Assigned	May be appropriate	●
Fluoroscopy single contrast esophagram	1-10 mSv ☠☠☠	Not Assigned	May be appropriate	●
Esophageal transit nuclear medicine scan	1-10 mSv ☠☠☠	Not Assigned	May be appropriate	●
Fluoroscopy pharynx dynamic and static imaging	1-10 mSv ☠☠☠	Not Assigned	Usually not appropriate	●
CT neck and chest with IV contrast	10-30 mSv ☠☠☠☠	Not Assigned	Usually not appropriate	●
CT neck and chest without IV contrast	10-30 mSv ☠☠☠☠	Not Assigned	Usually not appropriate	●
CT neck and chest without and with IV contrast	10-30 mSv ☠☠☠☠	Not Assigned	Usually not appropriate	●

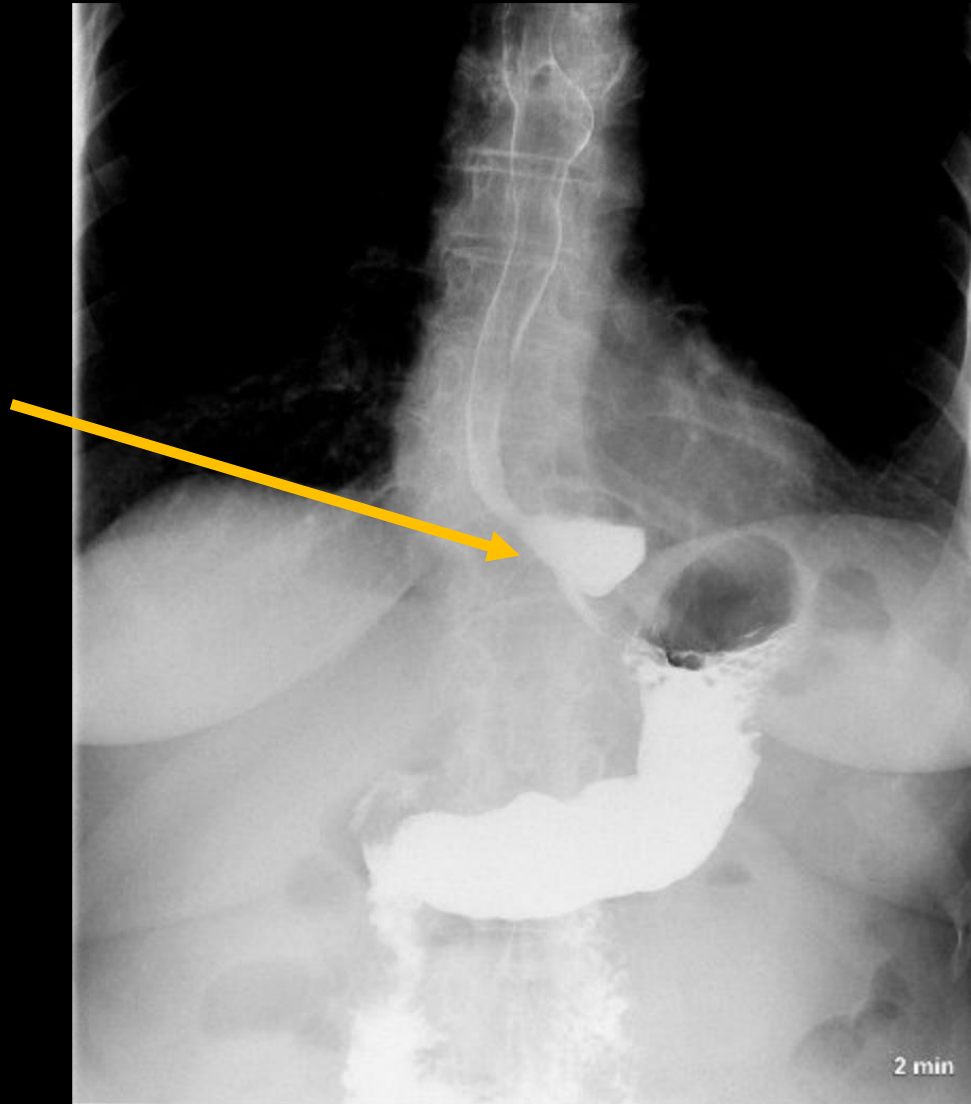
This imaging modality was ordered

Findings (unlabeled)



Findings: (labeled)

Upper GI fluoroscopic exam showing a distal thoracic esophageal diverticulum measuring approximately 2.2 x 2.1 cm



Final Dx:

Epiphrenic Diverticulum

Epiphrenic Diverticulum

- **Etiology:** Epiphrenic diverticulum is a pseudodiverticulum occurring within the distal 10cm of the esophagus. Peristaltic contractions cause increased intraluminal pressure against weakened esophageal musculature forcing bolus into an outpouching. They are commonly concomitant with underlying esophageal motility issues such as esophageal strictures, esophageal webs, or achalasia (75% of cases).
- **Clinical presentation:** Typically an asymptomatic presentation (~75%). There is minimal correlation between the size of diverticula and symptom severity. Patients can experience dysphagia, regurgitation, cough, or retrosternal pain. However, these symptoms are thought to evolve from underlying associated diagnosis, not the diverticulum. The physical exam will be unremarkable.
- **Differential Diagnosis:** GERD, esophageal stricture, hiatal hernia, malignancy, esophagitis, and peptic ulcer

Diagnosis

- **Biphasic Esophagram:** Proximal esophageal distension; spherical protrusion of distal esophagus; filling and retention of contrast in esophagus and diverticulum
- **Upper Endoscopy:** One or many diverticula visualized in the distal esophagus

Treatment

- **Conservative:**

- Observation
- Dietary management: avoid spicy foods, chew thoroughly, and drink copious water during and after meals
- Medication management: prescribe crushed or liquid form H₂-blockers or proton pump inhibitors

- **Surgical:**

- Peroral Endoscopic Myotomy (POEM): Endoscope passes through mouth in order to perform LES myotomy
- Heller myotomy: Laparoscopic surgical division of LES muscles to allow food to pass into stomach (92% symptomatic relief of dysphagia)
 - Consider Nissen Fundoplication to prevent development of GERD

References:

- <https://www.acr.org/Clinical-Resources/ACR-Appropriateness-Criteria>
- Chuah SK, Wu KL, Hu TH, Tai WC, Changchien CS. Endoscope-guided pneumatic dilation for treatment of esophageal achalasia. *World J Gastroenterol*. 2010;16(4):411-417. doi:10.3748/wjg.v16.i4.411
- Abdollahimohammad A, Masinaeinezhad N, Firouzkouhi M. Epiphrenic esophageal diverticula. *J Res Med Sci*. 2014;19(8):795-797.
- Herbella FA, Patti MG. Achalasia and epiphrenic diverticulum. *World J Surg*. 2015;39(7):1620-1624. doi:10.1007/s00268-015-2949-0
- Nadaletto BF, Herbella FAM, Patti MG. Treatment of Achalasia and Epiphrenic Diverticulum. *World J Surg*. 2022;46(7):1547-1553. doi:10.1007/s00268-022-06476-2
- Zaninotto G, Portale G, Costantini M, Zanatta L, Salvador R, Ruol A. Therapeutic strategies for epiphrenic diverticula: systematic review. *World J Surg*. 2011;35(7):1447-1453. doi:10.1007/s00268-011-1065-z
- Robson, K, Fedorowicz, Z, and Ehrlich, A. DnaMed. Achalasia. EBSCO Information Services. Accessed February 2, 2023. <https://www.dynamed.com/condition/achalasia>
- Ehrlich, A. DynaMed. Esophageal Diverticula. EBSCO Information Services. Accessed February 2, 2023. <https://www.dynamed.com/condition/esophageal-diverticula>
- Peroral Endoscopic Myotomy (POEM). Johns Hopkins
- <https://my.clevelandclinic.org/health/diseases/16977-esophageal-diverticulum>
- Constantin A, Constantinoiu S, Achim F, Socea B, Costea DO, Predescu D. Esophageal diverticula: from diagnosis to therapeutic management-narrative review. *J Thorac Dis*. 2023;15(2):759-779. doi:10.21037/jtd-22-861
- Medicine. <https://www.hopkinsmedicine.org/health/treatment-tests-and-therapies/peroral-endoscopic-myotomy>. Accessed 2/2/2023