



AMSER Rad Path Case of the Month:



PHILADELPHIA
COLLEGE OF
OSTEOPATHIC
MEDICINE™

44-year-old female with bilateral ovarian masses

Bryanna Guthridge, OMS4
Philadelphia College of Osteopathic Medicine

Dr. Matthew Hartman, MD, Department of Radiology
Allegheny Health Network

Dr. Christopher Morse, MD, Division of Gynecologic Oncology
Allegheny Health Network

Dr. Sharon Liang, MD, PhD, Department of Pathology
Allegheny Health network



Patient Presentation

HPI: A 44-year-old female presented to the emergency department with acute-onset right-sided flank pain radiating into the pelvis. A non-contrast CT showed a pinpoint calculus near the UVJ in addition to a large complex unilateral vs bilateral cystic pelvic mass extending into the abdomen. This cystic structure was again identified by pelvic ultrasound.

PMH: Nephrolithiasis

PSH: Repair of pelvic and arm fractures

Social History: Current PPD smoker

Physical Exam: Abdomen soft, flat, and non-tender. On bimanual exam, there is a palpable large ovarian mass to the level of the umbilicus.

Pertinent Labs: CA-125- 243

What Imaging Should We Order?

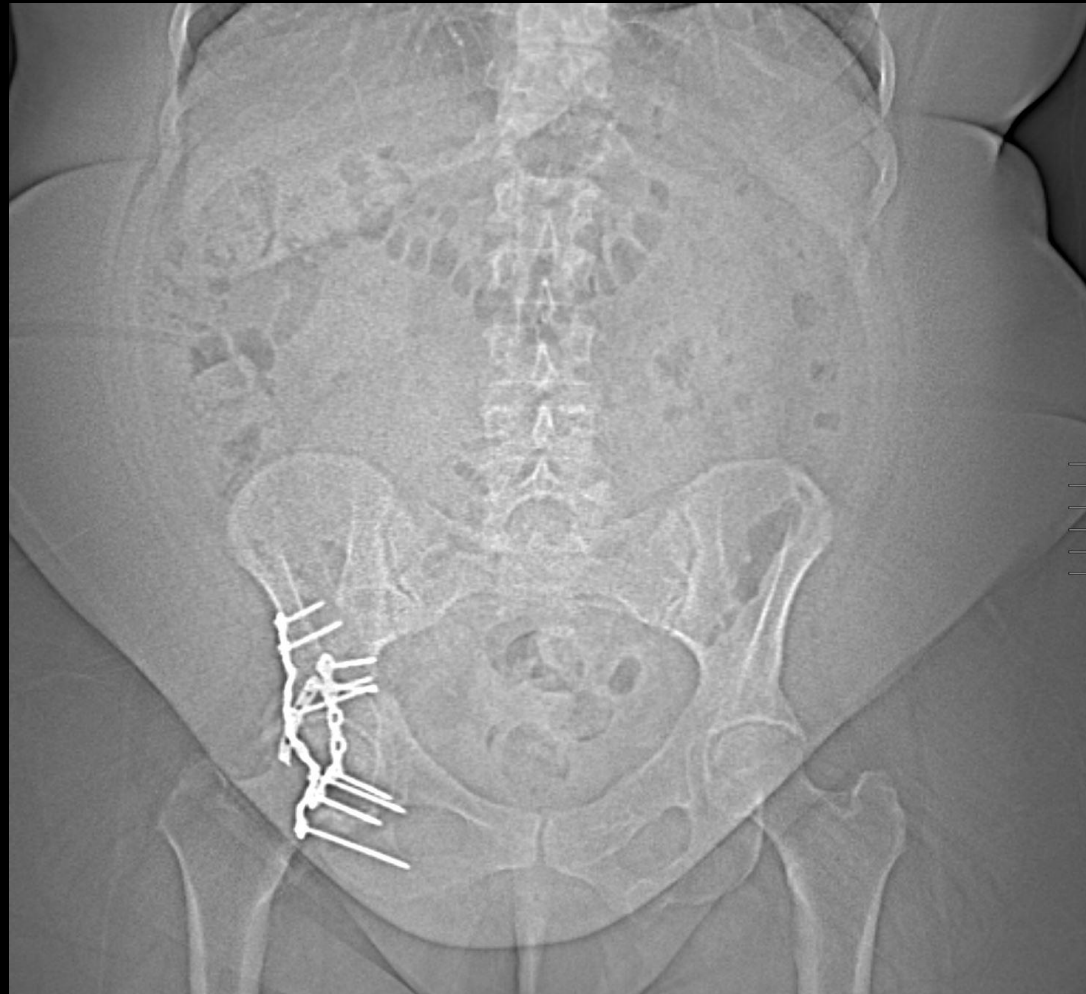ACR Appropriateness Criteria

Variant 7:

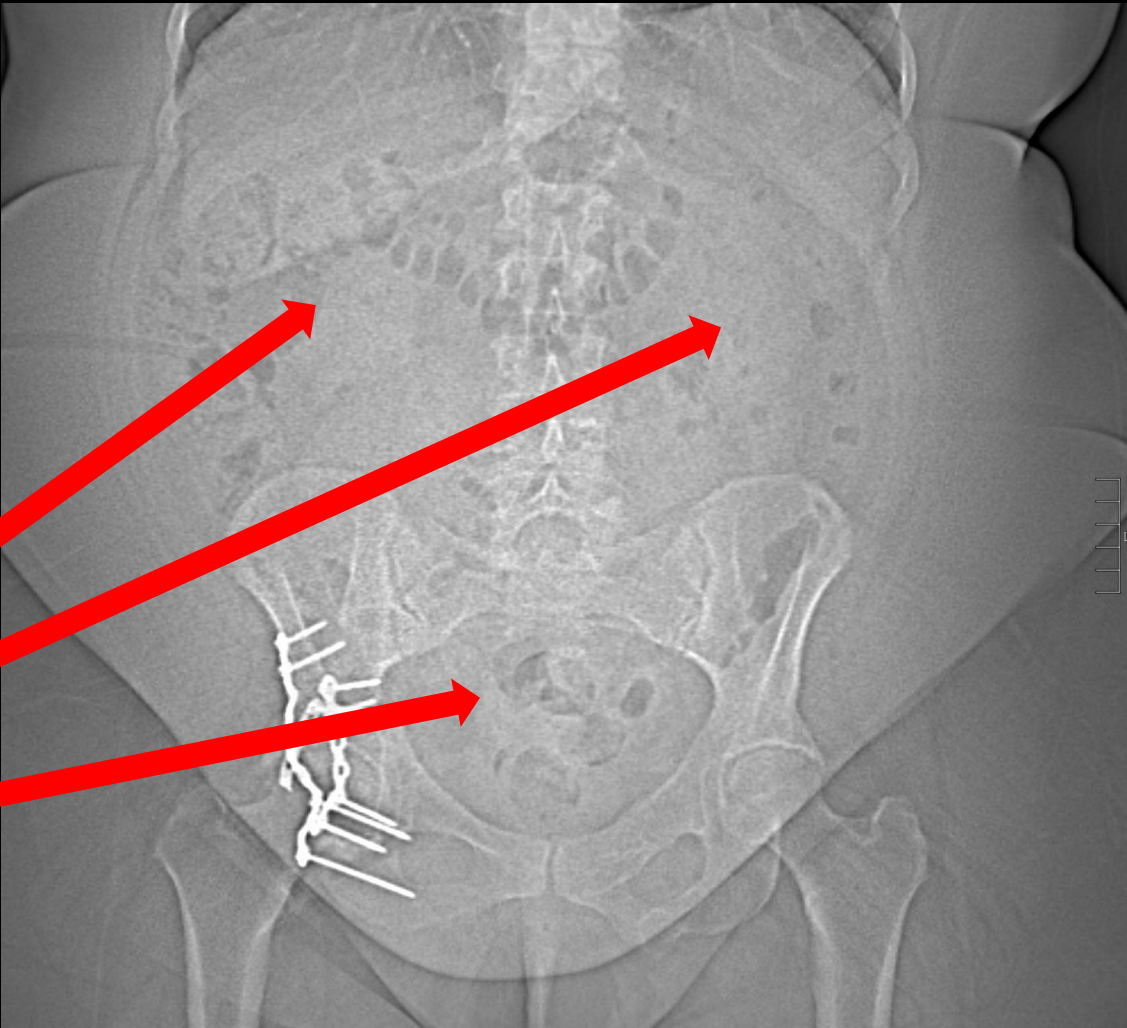
Adnexal mass, highly suspicious for malignancy, no acute symptoms. Premenopausal and postmenopausal. Initial follow-up.

Procedure	Appropriateness Category	Relative Radiation Level
CT abdomen and pelvis with IV contrast	Usually Appropriate	☼☼☼
MRI pelvis without and with IV contrast	Usually Appropriate	○
US pelvis transabdominal	May Be Appropriate	○
US pelvis transvaginal	May Be Appropriate	○
CT pelvis with IV contrast	May Be Appropriate (Disagreement)	☼☼☼
CT pelvis without and with IV contrast	May Be Appropriate (Disagreement)	☼☼☼☼
FDG-PET/CT skull base to mid-thigh	May Be Appropriate	☼☼☼☼
MRI pelvis without IV contrast	May Be Appropriate	○
US duplex Doppler pelvis	May Be Appropriate (Disagreement)	○
CT abdomen and pelvis without IV contrast	May Be Appropriate	☼☼☼
CT abdomen and pelvis without and with IV contrast	Usually Not Appropriate	☼☼☼☼
CT pelvis without IV contrast	Usually Not Appropriate	☼☼☼

Scout Abdominal X-ray (unlabeled)



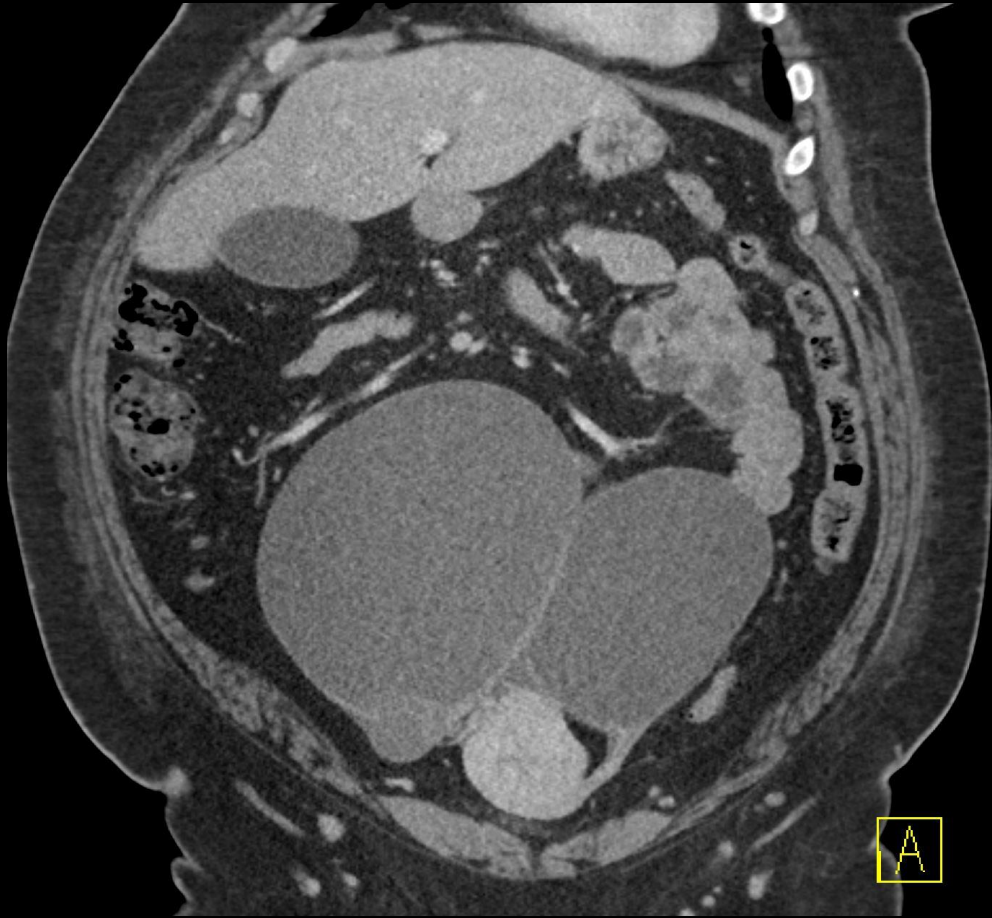
Scout Abdominal X-ray (labeled)



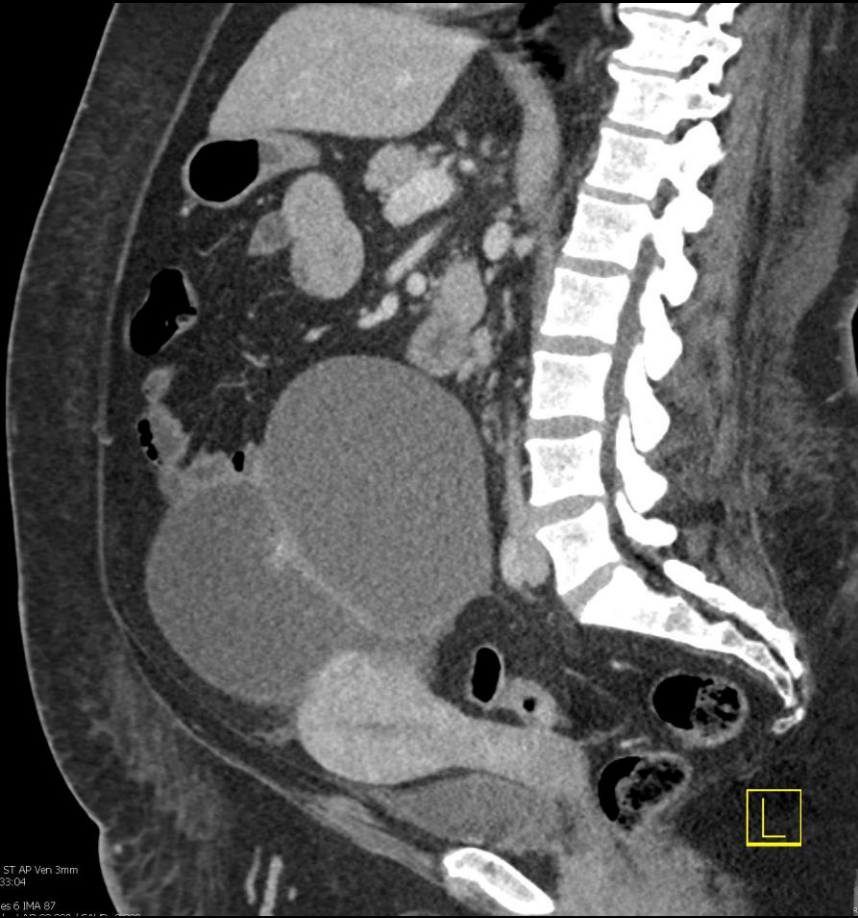
Intestines displaced
around pelvic
mass/masses

Scant bowel gas
due to mass effect

CT Abdomen with IV Contrast (unlabeled)

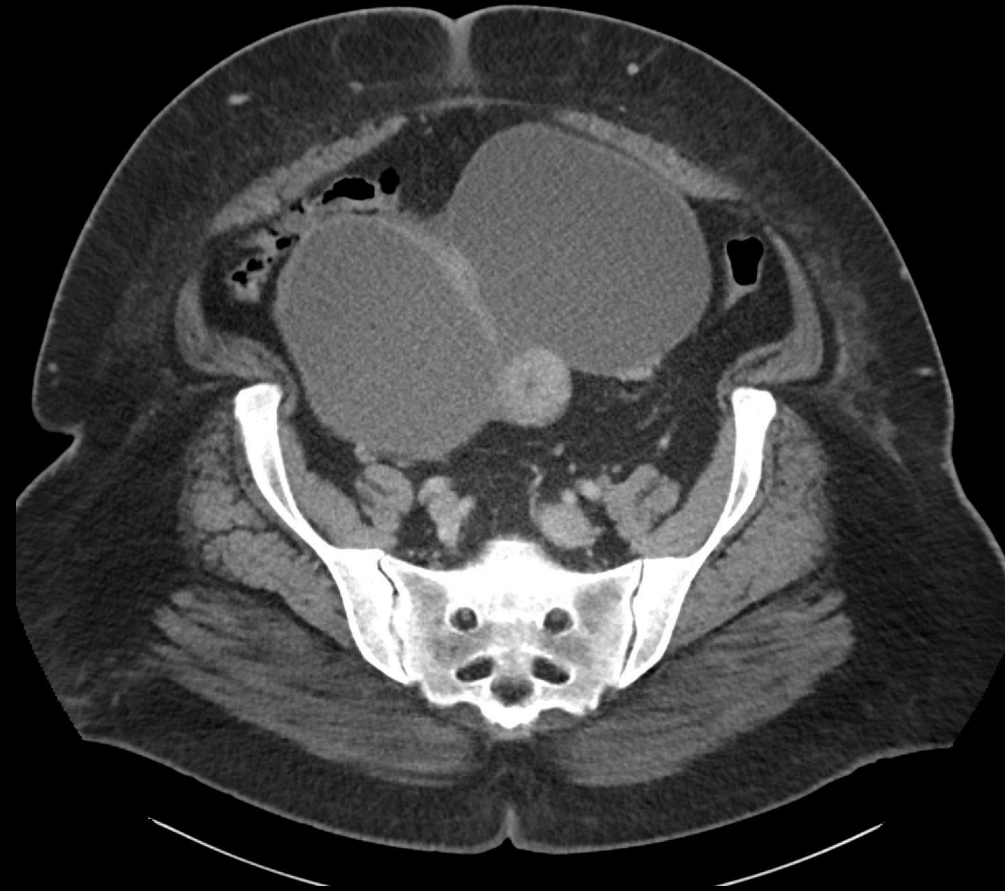


Coronal



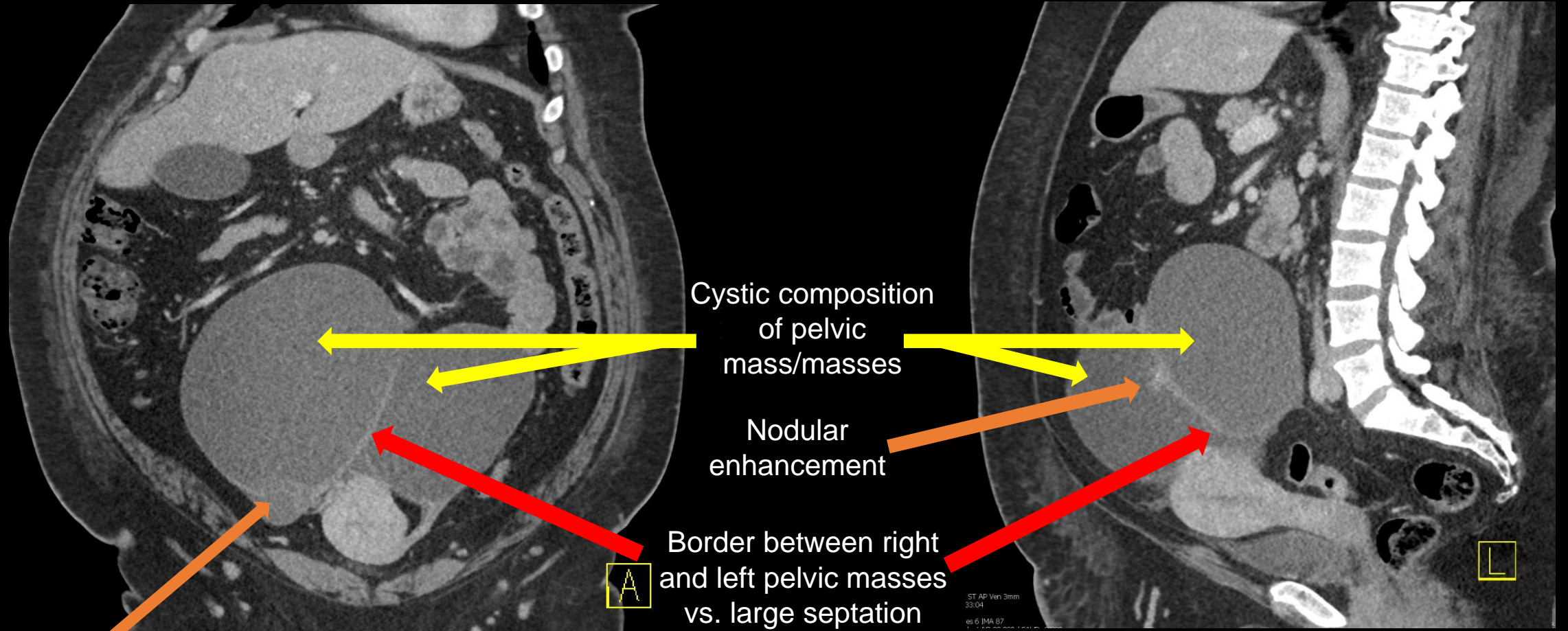
Sagittal

CT Abdomen with IV Contrast (unlabeled)



Axial

CT Abdomen with IV Contrast (labeled)



Cystic composition
of pelvic
mass/masses

Nodular
enhancement

Border between right
and left pelvic masses
vs. large septation
within unilateral mass

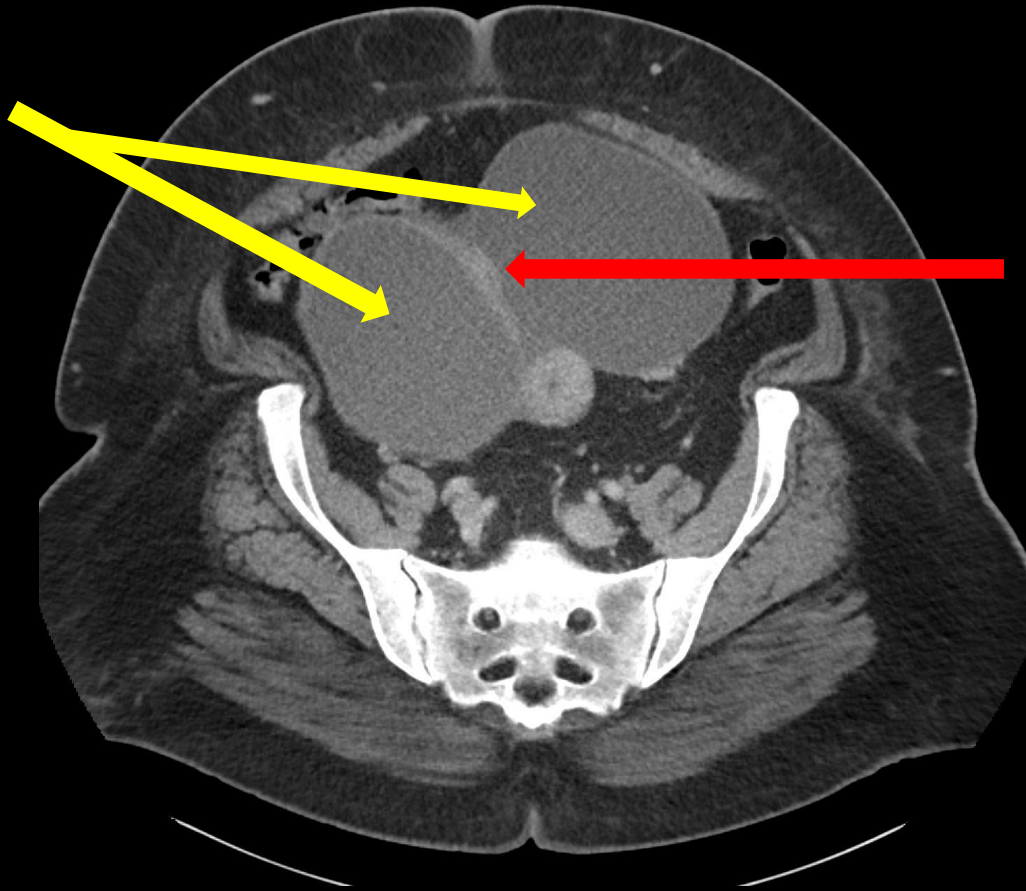
Septations/nodularity
in lower pole of mass

Coronal

Sagittal

CT Abdomen with IV Contrast (labeled)

Cystic
composition of
mass/masses



Border between right
and left pelvic masses
vs. large septation
within unilateral mass

Axial

DDX (based on imaging)

1. Bilateral/unilateral ovarian cystadenoma
2. Bilateral/unilateral cystadenocarcinoma
3. Bilateral/unilateral borderline ovarian neoplasm
4. Pelvic lymphoceles
5. Cystic metastases

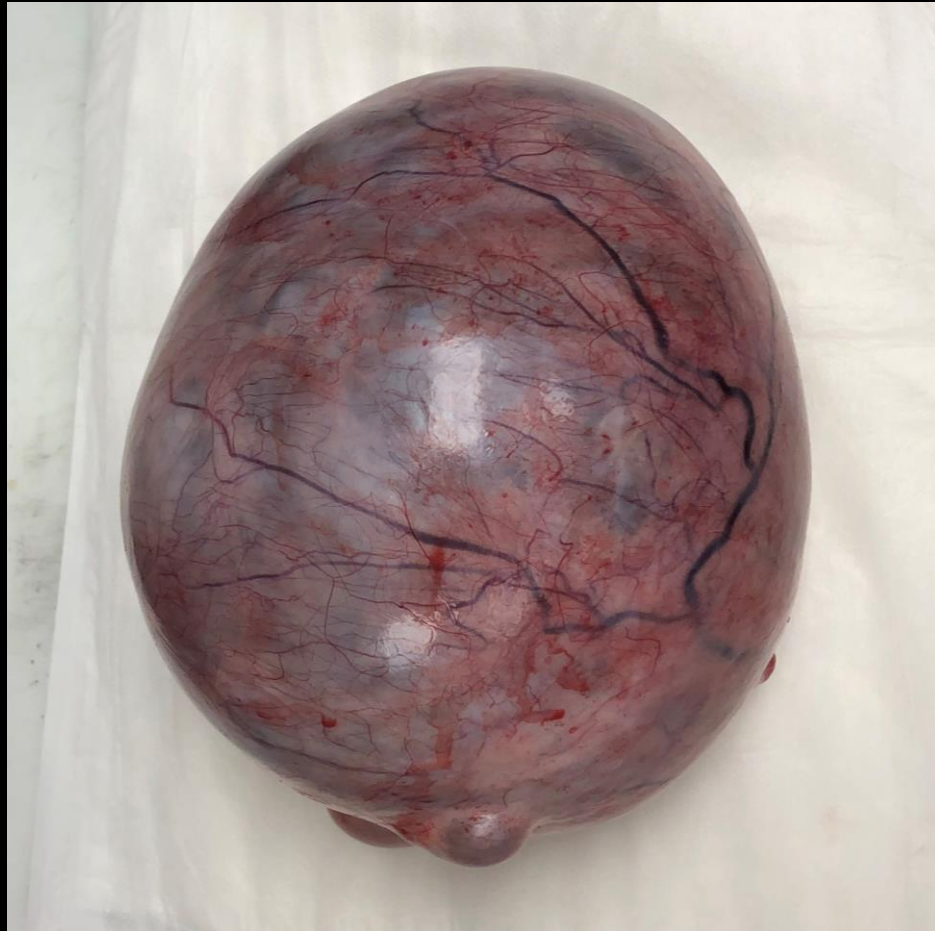Operative Management

Procedure: Exploratory laparotomy, total abdominal hysterectomy, bilateral salpingo-oophorectomy with resection of adnexal masses, and infra-colic omentectomy.

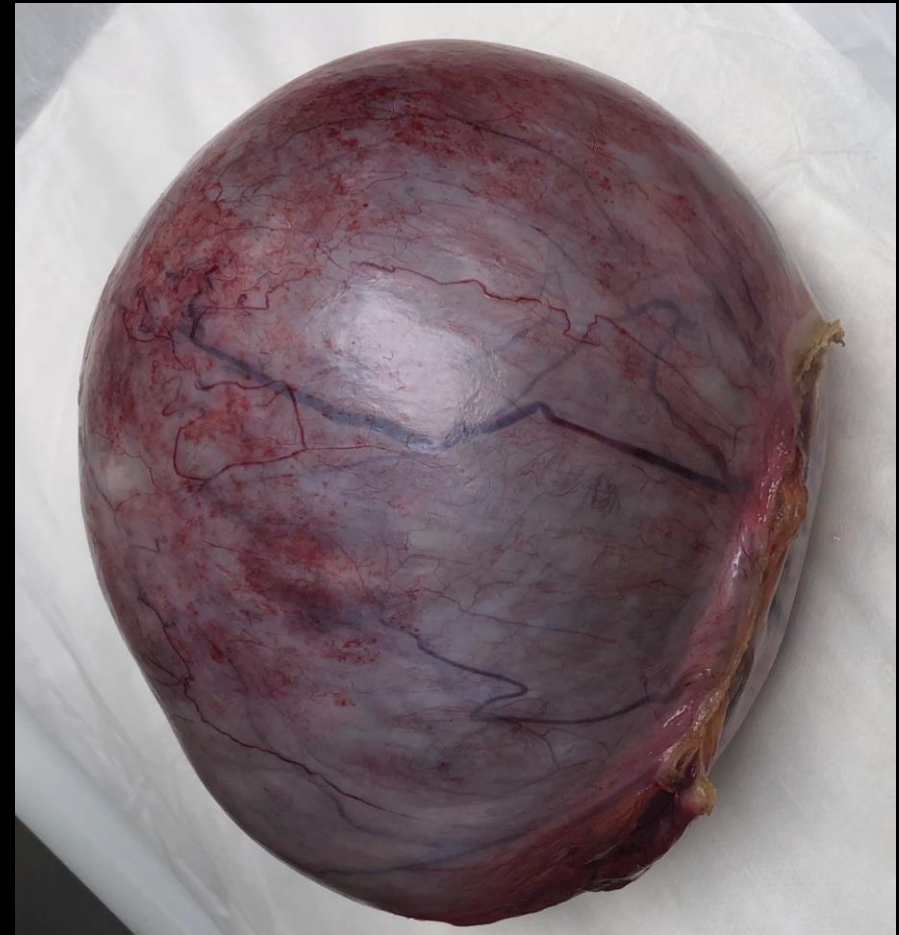Intra-Operative Findings: Two large adnexal masses measuring approximately 10 cm on the left and 15 cm on the right. The left adnexal mass was mobile. The right adnexal mass was somewhat adhered to the posterior pelvic peritoneum. The liver, diaphragm, gallbladder, omentum, fallopian tubes, and bowel were all normal in appearance. There was no evidence of ascites or peritoneal disease. The uterus was normal in size with a posterior fibroid.

Estimated Blood Loss: 250 mL

Gross Pathology

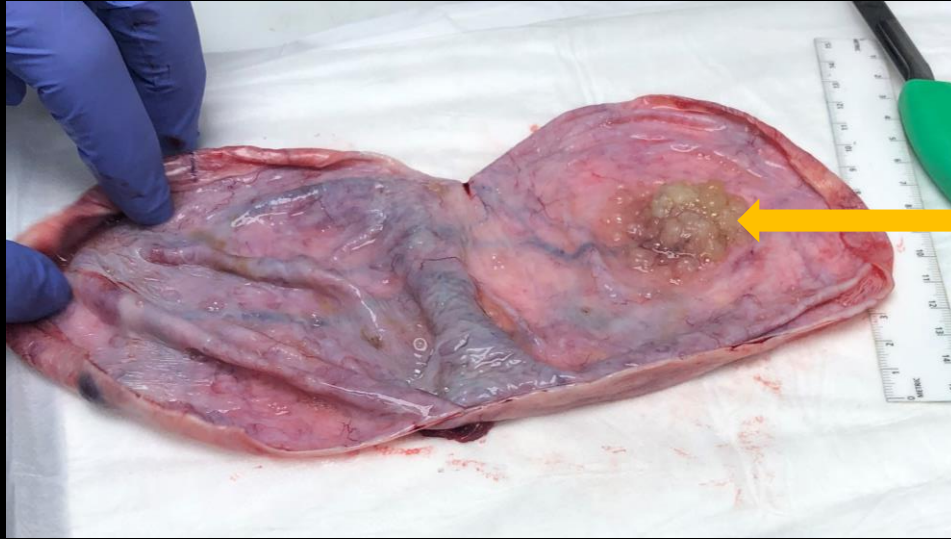

Right ovary and mass

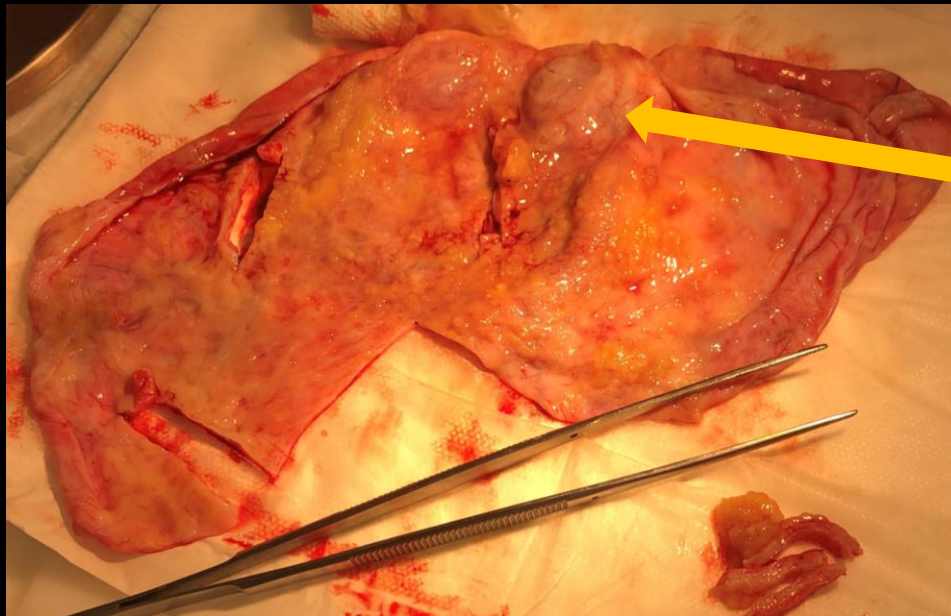


Left ovary and mass

Gross Pathology

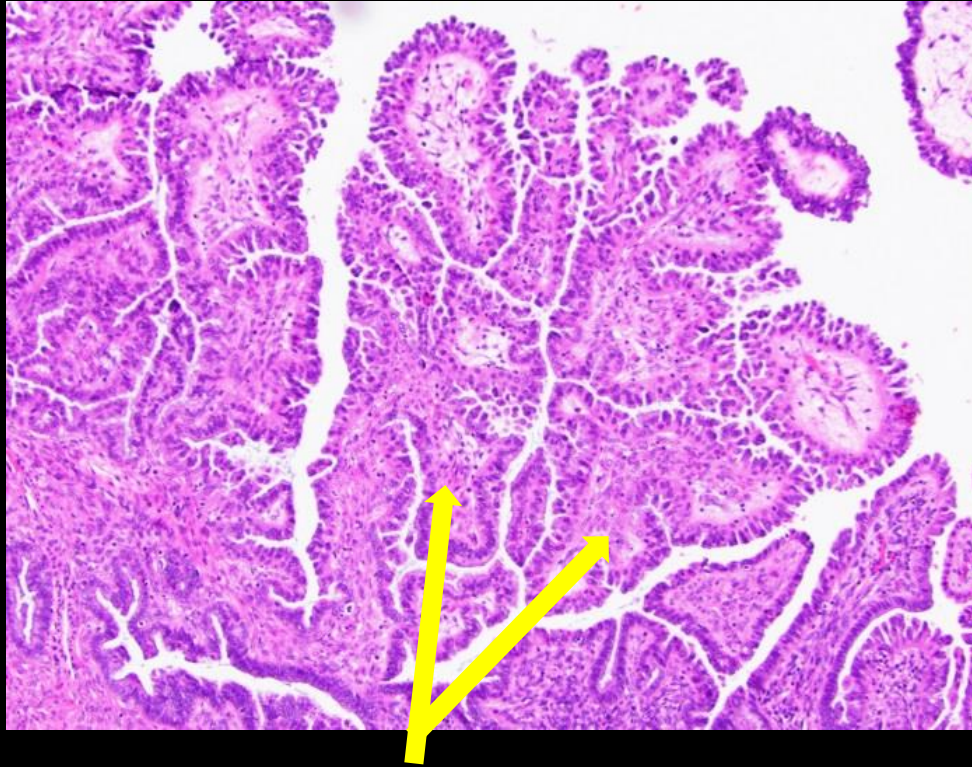


Cut surface of left mass after drainage of cystic fluid with area of nodularity

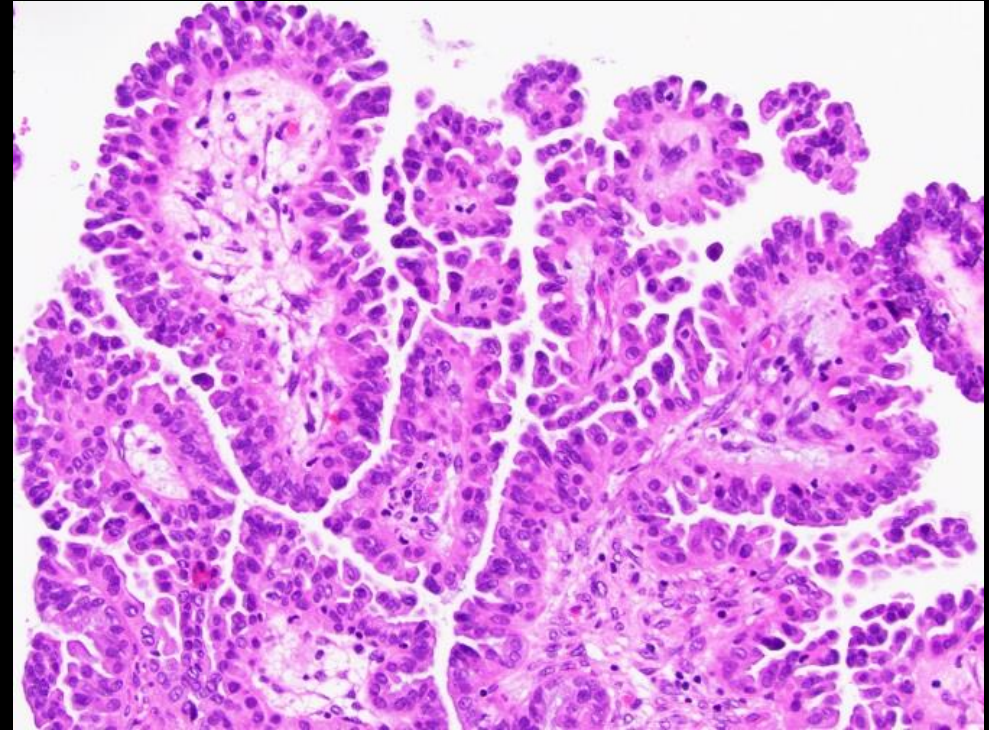


Cut surface of right mass after drainage of cystic fluid with some areas of septation/nodularity

Micro Path (labeled)



- H&E stain demonstrating numerous papillary structures branching into smaller papillae with no invasion into surrounding stroma (100x amplification)



- The epithelium lining the papillae is proliferative but relatively uniform with minimal nuclear atypia (200x amplification)

Final Dx:

Bilateral Borderline Serous Ovarian Tumors

Case Discussion: Borderline Serous Ovarian Tumors

- **Epidemiology:** Borderline ovarian tumors tend to occur in younger females (avg age= 45 years) when compared to ovarian epithelial cancer (avg age= 55 years). The majority of borderline tumors are of serous (53.3%) histology. Of all serous tumors, borderline tumors make up 10-15% with up to 1/3 of cases being bilateral.
- **Presentation:** Patients may present with pelvic or abdominal pain/pressure in addition to dyspareunia. Some cases are also discovered incidentally in asymptomatic patients.

Case Discussion: Borderline Serous Ovarian Tumors

- **Pathology:** Epithelial ovarian tumors are derived from the ovarian or tubal surface epithelium. Borderline serous epithelial tumors are of low malignant potential and are classified histologically by exuberant cellular proliferation with no invasive behavior. When compared to benign serous tumors, they have more excessive and finer papillary projections. Borderline tumors can occasionally display aggressive behavior with peritoneal or nodal metastases.

Case Discussion: Borderline Serous Ovarian Tumors

- **Treatment:** Management of borderline ovarian tumors is surgical. Extent of surgical resection depends on the patients desires for future fertility, presence of bilateral ovarian involvement, and degree of disease spread. Definitive treatment is total abdominal hysterectomy with bilateral salpingo-oophorectomy. Frozen sections during surgery are important to guide further operative management. Lymph node dissection is typically omitted unless there is concern for malignancy on frozen section.
- **Imaging:** The best initial imaging for all ovarian masses is endovaginal ultrasound. Borderline serous tumors are usually seen as bilateral adnexal masses with papillary projections sometimes demonstrating intratumoral blood flow.

References:

- ACR appropriateness criteria®. American College of Radiology. <https://www.acr.org/Clinical-Resources/ACR-Appropriateness-Criteria>. Accessed August 25, 2022.
- Chen, V.W., Ruiz, B., Killeen, J.L., Coté, T.R., Wu, X.C., Correa, C.N. and Howe, H.L. (2003), Pathology and classification of ovarian tumors. *Cancer*, 97: 2631-2642. <https://doi.org/10.1002/cncr.11345>
- Fischerova D, Zikan M, Dundr P, Cibula D. Diagnosis, treatment, and follow-up of borderline ovarian tumors. *The Oncologist*. 2012;17(12):1515-1533. doi:10.1634/theoncologist.2012-0139
- Taylor EC, Irshaid L, Mathur M. Multimodality imaging approach to ovarian neoplasms with pathologic correlation. *RadioGraphics*. 2021;41(1):289-315. doi:10.1148/rg.2021200086
- Tinelli R, Tinelli A, Tinelli FG, Cicinelli E, Malvasi A. Conservative surgery for borderline ovarian tumors: A Review. *Gynecologic Oncology*. 2006;100(1):185-191. doi:10.1016/j.ygyno.2005.09.021
- Seong SJ, Kim DH, Kim MK, Song T. Controversies in borderline ovarian tumors. *Journal of Gynecologic Oncology*. 2015;26(4):343. doi:10.3802/jgo.2015.26.4.343