

# AMSER Case of the Month

## July 2022

# Carotid-Cavernous Fistula Diagnosis and Management

Faraz Farzad, University of Virginia School of Medicine

Dr. Wayne Dell, University of Virginia Health System

Dr. Tanvir Rizvi, University of Virginia Health System



# Patient Presentation

- 69 year old female presents to ophthalmology clinic with complaints of persistent right conjunctival injection and swelling over the past 6 months. Patient also suffered from intermittent diplopia and blurry vision. A course of steroids improved the swelling, but redness has persisted in spite of over the counter remedies.
- On exam, patients has right sided conjunctival injection, right sided proptosis, and isolated right sided elevated intraocular pressure. Pupils are reactive to light. On cranial nerve exam, patient is unable to abduct her right eye.

What Imaging Should We Order?

# Select the applicable ACR Appropriateness Criteria

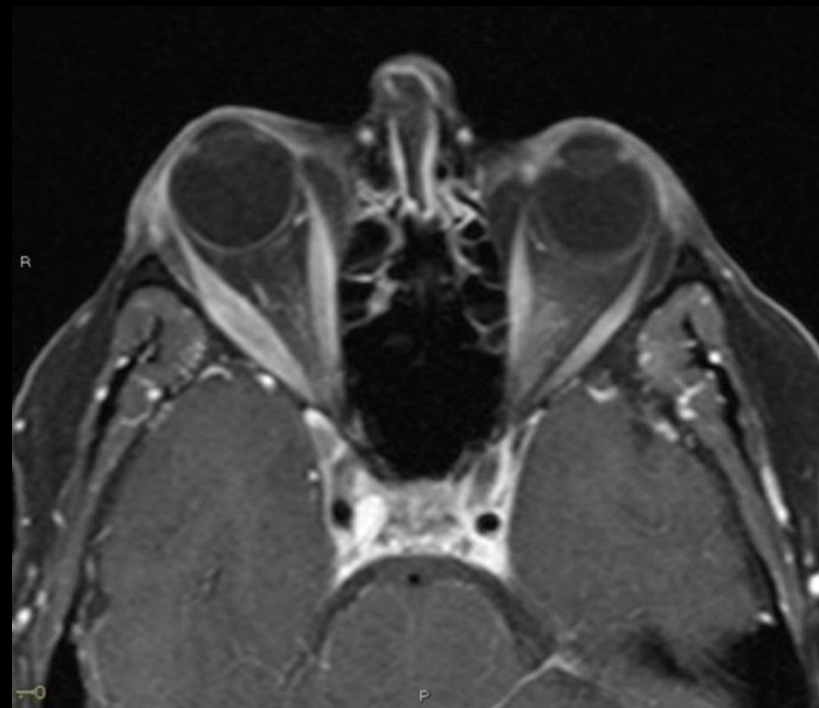
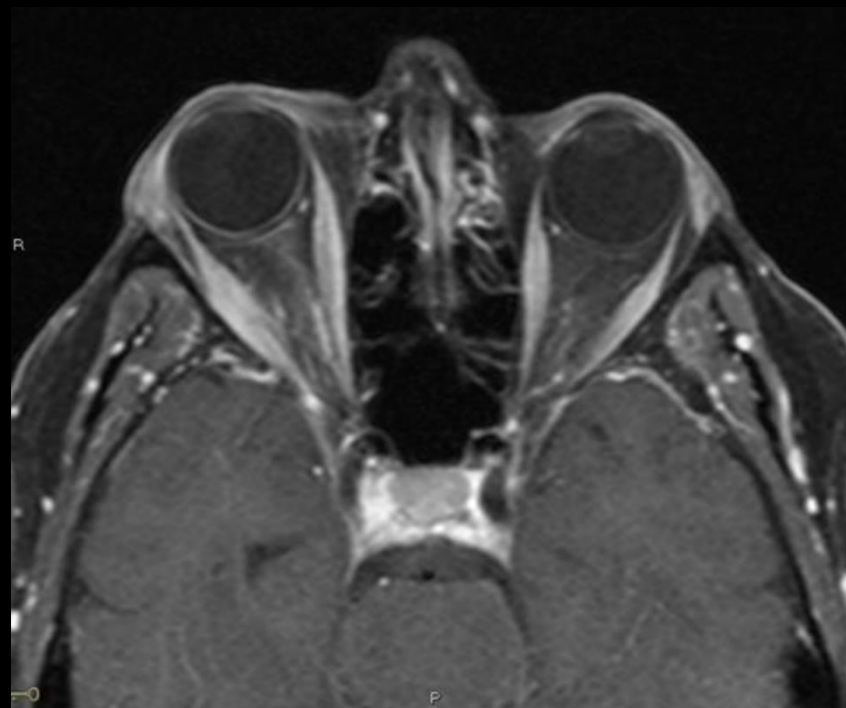
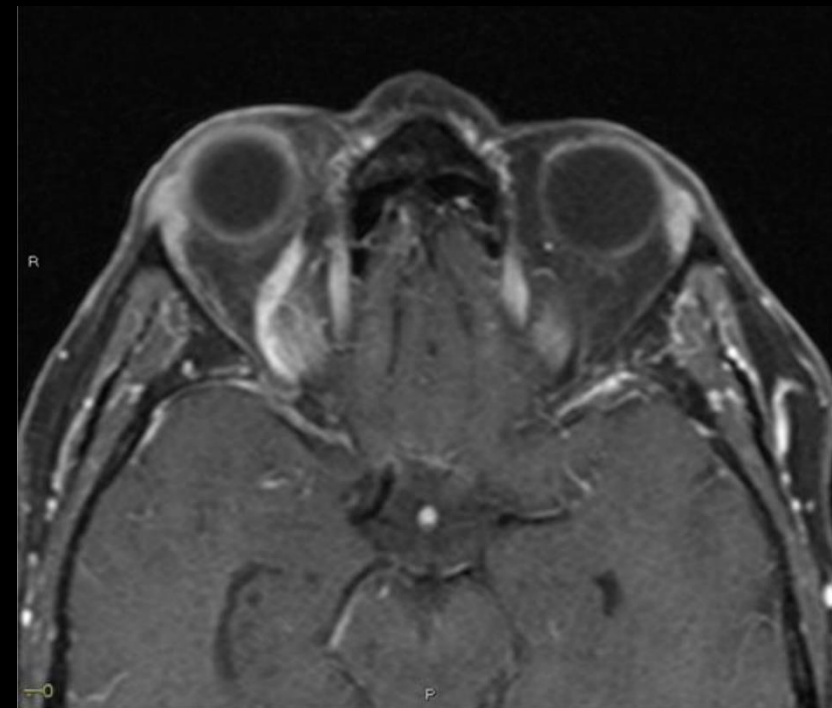
**Variant 2:** Nontraumatic orbital asymmetry, exophthalmos, or enophthalmos. Initial imaging.

Procedure	Appropriateness Category	RRL
MRI orbits without and with IV contrast	Usually Appropriate	O
CT orbits with IV contrast	Usually Appropriate	⊗ ⊗ ⊗
CT orbits without IV contrast	May Be Appropriate	⊗ ⊗ ⊗
CTA head and neck with IV contrast	May Be Appropriate	⊗ ⊗ ⊗
MRA head and neck without and with IV contrast	May Be Appropriate	O
MRI head without and with IV contrast	May Be Appropriate	O
MRI orbits without IV contrast	May Be Appropriate	O
MRA head and neck without IV contrast	May Be Appropriate (Disagreement)	O
MRI head without IV contrast	May Be Appropriate	O
Arteriography cervicocerebral	May Be Appropriate	⊗ ⊗ ⊗
CT head with IV contrast	May Be Appropriate	⊗ ⊗ ⊗
CT head without IV contrast	May Be Appropriate	⊗ ⊗ ⊗
CT head without and with IV contrast	Usually Not Appropriate	⊗ ⊗ ⊗
CT orbits without and with IV contrast	Usually Not Appropriate	⊗ ⊗ ⊗
X-ray orbit	Usually Not Appropriate	⊗

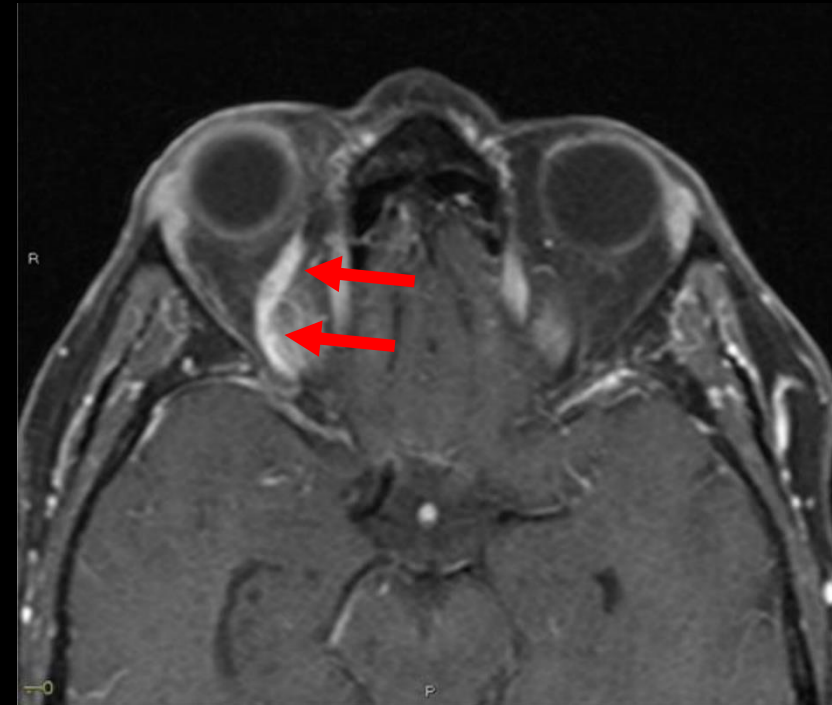


This imaging modality was ordered by the ophthalmologist

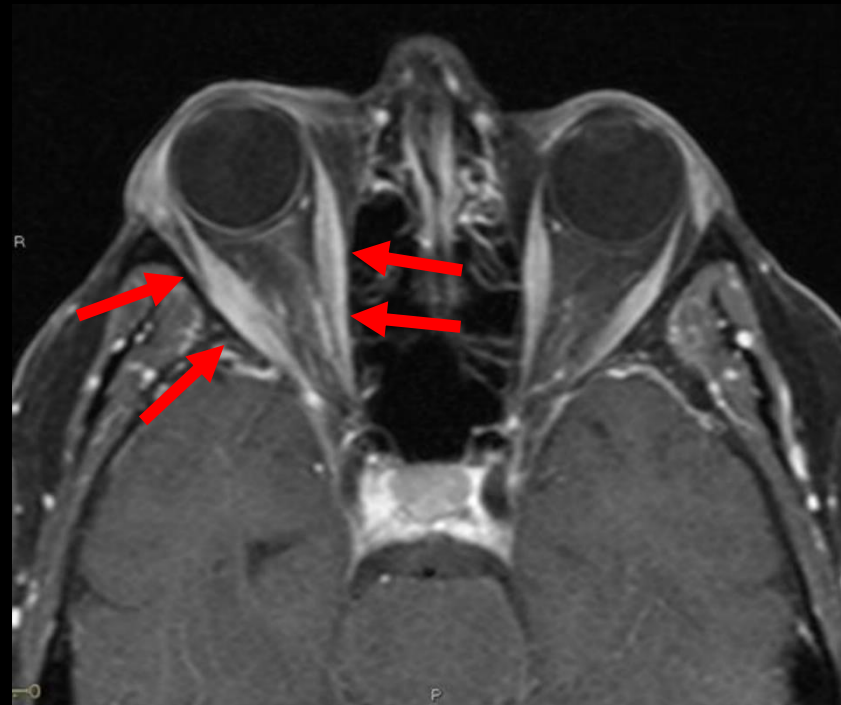
# Findings (unlabeled)



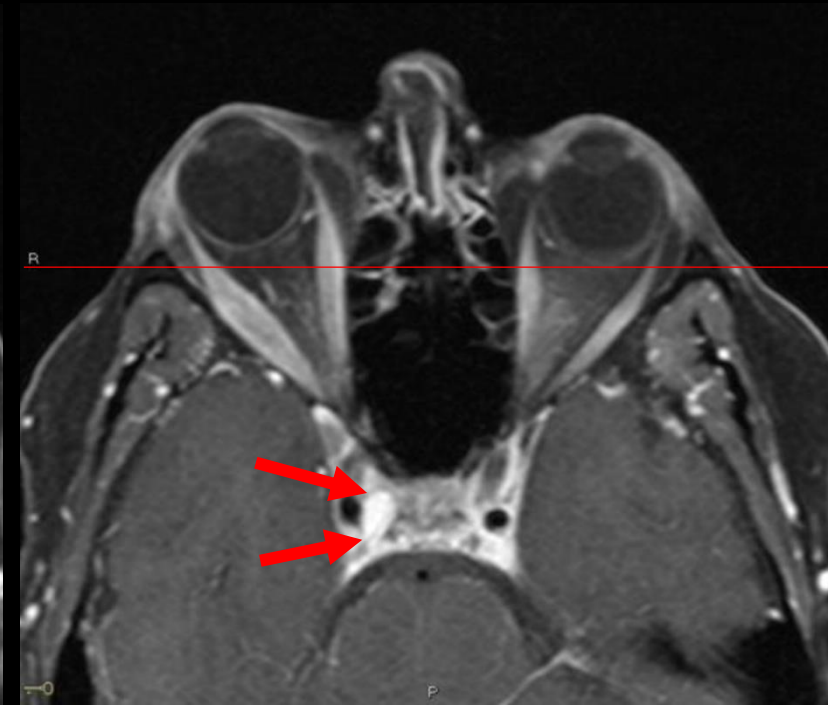
# Findings (labeled)



Dilated but patent right superior ophthalmic vein



Mild right sided retrobulbar fat stranding with enlargement of the extraocular muscles



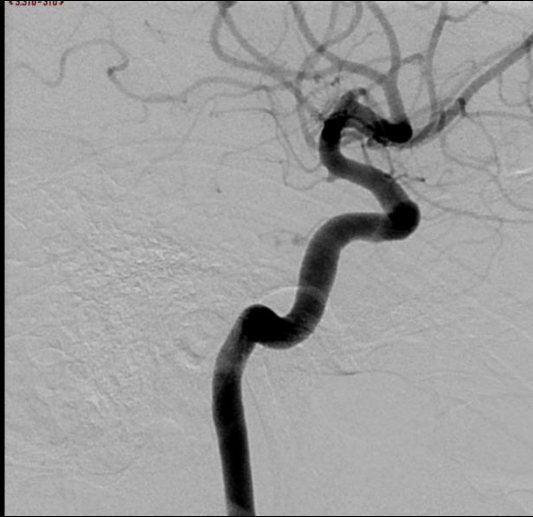Medial right cavernous sinus postcontrast enhancement and right sided proptosis

## Initial Dx:

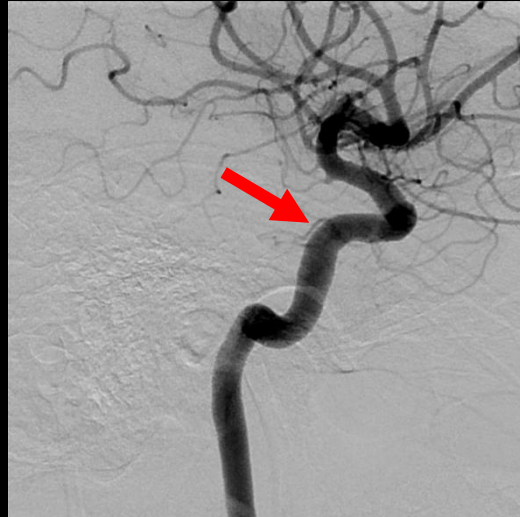Cavernous carotid fistula vs chronic cavernous sinus thrombosis

Cerebral angiogram was scheduled for confirmation of diagnosis, and potential treatment.

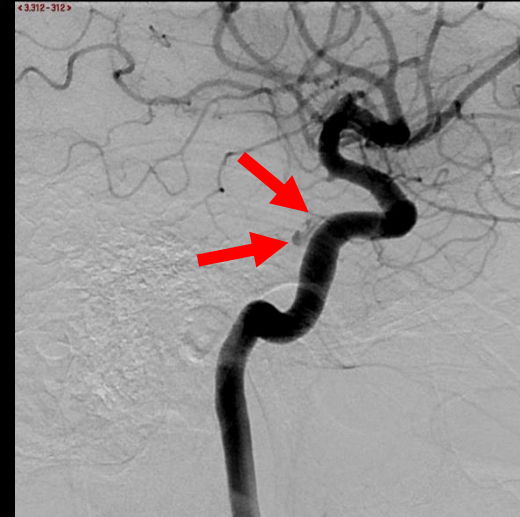# Follow up Imaging



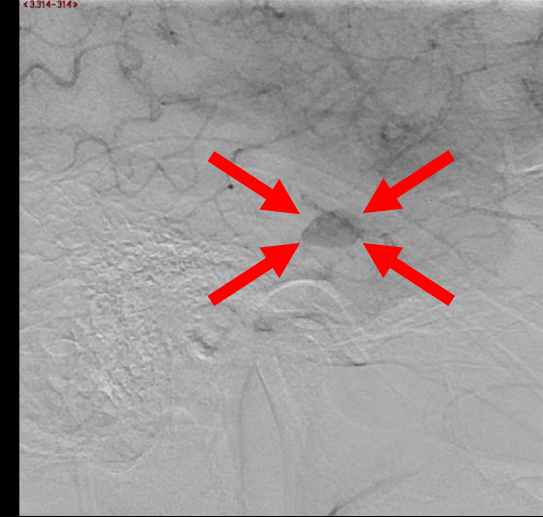
Filling of the right ICA



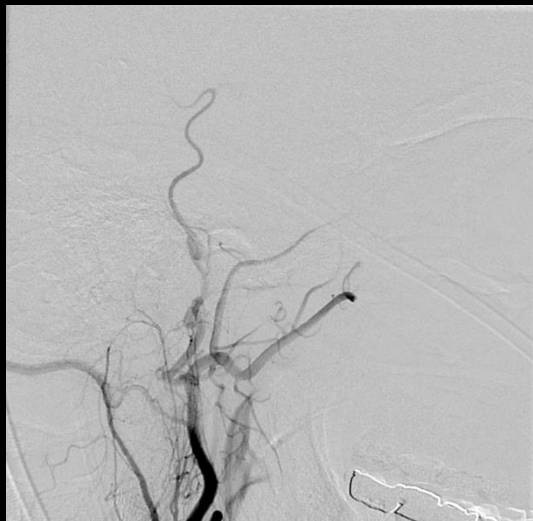Filling of the inferolateral trunk from the ICA



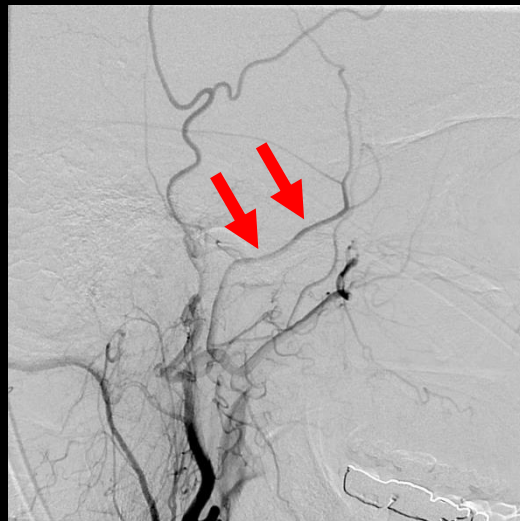Early leak into the cavernous sinus, likely from the inferolateral trunk



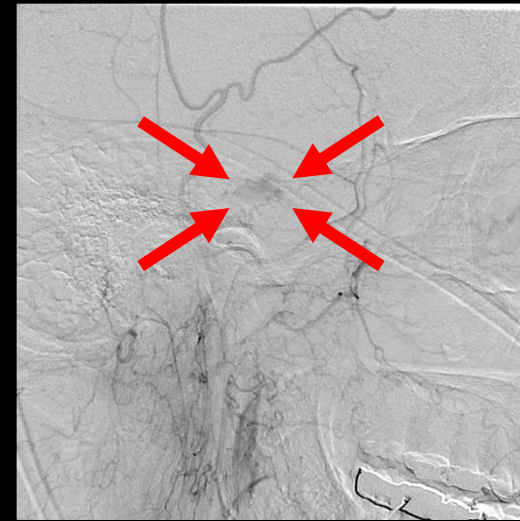Persisting contrast in the cavernous sinus



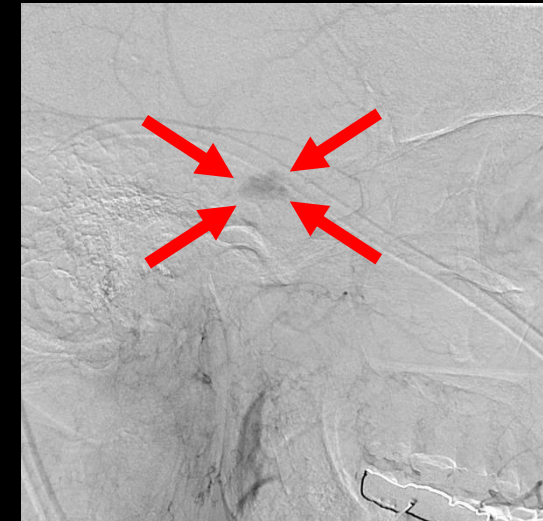Filling of the right ECA



Filling of the right middle meningeal artery from the ECA



Early leak into the cavernous sinus, likely from the middle meningeal artery



Persisting contrast in the cavernous sinus



# Case Discussion

- Carotid-cavernous fistulas (CCF) can be formed spontaneously or due to a traumatic insult. They allow shunting of arterial blood from the internal carotid artery (ICA) or external carotid artery (ECA) into the cavernous sinus.
- 75% are due to trauma
  - 0.2% of patients with craniocerebral trauma and 4% of patients with basilar skull fractures develop CCF
- Spontaneous CCF are less common and found in older, female patients.
  - Associated with cavernous carotid aneurysms
  - Can be due to chronic venous thrombosis with revascularization and thus are similar to dural arteriovenous fistulas..

# Classification

- Hemodynamic status: high flow vs low flow
- Cause: spontaneous vs traumatic
- Anatomical: direct vs indirect (from branches of carotid)

	Indirect vs Direct	High Flow vs Low Flow	Site of Fistula
Type A	Direct	High	ICA
Type B	Indirect	Low	Branch of ICA
Type C	Indirect	Low	Branch of ECA
Type D	Indirect	Low	Branches of ICA and ECA

Our patient had a Type D CCF

# Management

- External manual compression: numerous case series have found repeated manual compression to be effective at fistula closure with symptom relief.
  - Success rates vary between 17%-86% after 2 years.
- Endovascular intervention: trans-arterial or trans-venous embolization with the use of metal coils or other embolic agents.
  - More immediate results, but risks include cerebral infarction, hemorrhage, and transient worsening of symptoms
- Open surgical intervention: can be considered when less invasive options are not possible.
  - Invasive and associated with longer recovery times
- Radiosurgery: effective in treating indirect CCF with success rates reported as up to 90%. Less efficacious at treating direct CCF.

# References:

- Ellis J, Goldstein H, Connolly S, and Meyers P. Carotid-cavernous fistulas. *Neurosurgical Focus FOC* 32.5 (2012); E9. Web. < <https://doi.org/10.3171/2012.2.FOCUS1223>>.
- Mahalingam H, Mani S, Patel B, Prabhu K, Alexander M, Fatterpekar G, Chacko G. *RadioGraphics*. (2019); Vol 39. Web. <<https://pubs.rsna.org/doi/10.1148/rg.2019180122>>.
- Kalsi P, Padmanabhan R, Prasad K S M, Mukerji N. Treatment of low flow, indirect cavernous sinus dural arteriovenous fistulas with external manual carotid compression - the UK experience. *Br J Neurosurg*. (2020) Dec;34(6):701-703. doi: 10.1080/02688697.2020.1716947. Epub 2020 Feb 3. PMID: 32009471.
- Higashida RT, Hieshima GB, Halbach VV, Bentson JR, Goto K. Closure of carotid cavernous sinus fistulae by external compression of the carotid artery and jugular vein. *Acta Radiol Suppl*. (1986);369:580-3. PMID: 2980563.
- Barcia-Salorio J L, Soler F, Barcia J A, Hernández G. Stereotactic Radiosurgery for the Treatment of Low-Flow Carotid-Cavernous Fistulae: Results in a Series of 25 Cases. *Stereotact Funct Neurosurg* (1994);63:266-270. doi: 10.1159/000100330
- <https://radiopaedia.org/articles/caroticocavernous-fistula-1?lang=us>