

AMSER RAD PATH

Case of the Month:

71 y/o F with palpable perirectal mass

Allison Smith OMS-IV

Lake Erie College of Osteopathic Medicine

Matthew Hartman, MD

Medical Student Radiology Director Allegheny Health Network

Sarah Crafton, MD

Gynecologic Oncology, Allegheny Health Network

Sharon Liang, MD, PhD

Department of Pathology, Allegheny Health Network



Patient Presentation

HPI: 71 y/o female presents for LEEP procedure due to persistent abnormal pap smears. The procedure was aborted due to inability to visualize the cervix on exam.

OB/GYN Hx: G1P1001, postmenopausal, persistent abnormal pap smears

PMHx: Anemia, arthritis, thyroid disease, SVT

PSHx: Ablation for SVT, colonoscopy, colposcopy, gastric bypass, abdominoplasty, rectocele repair.

FHx: Uterine cancer in mother, negative for ovarian breast or colon cancer

Medications: Vitamin B12, levothyroxine

SHx: Former smoker (0.5 ppd for 15 years)

Physical Exam: Large palpable perirectal mass beginning at the area between the vagina and rectum 2-3 cm above the ring of the rectal sphincter, speculum exam deferred due to mass size.

Pertinent labs: CEA <1.8, CA-125 176

What Should We Order?

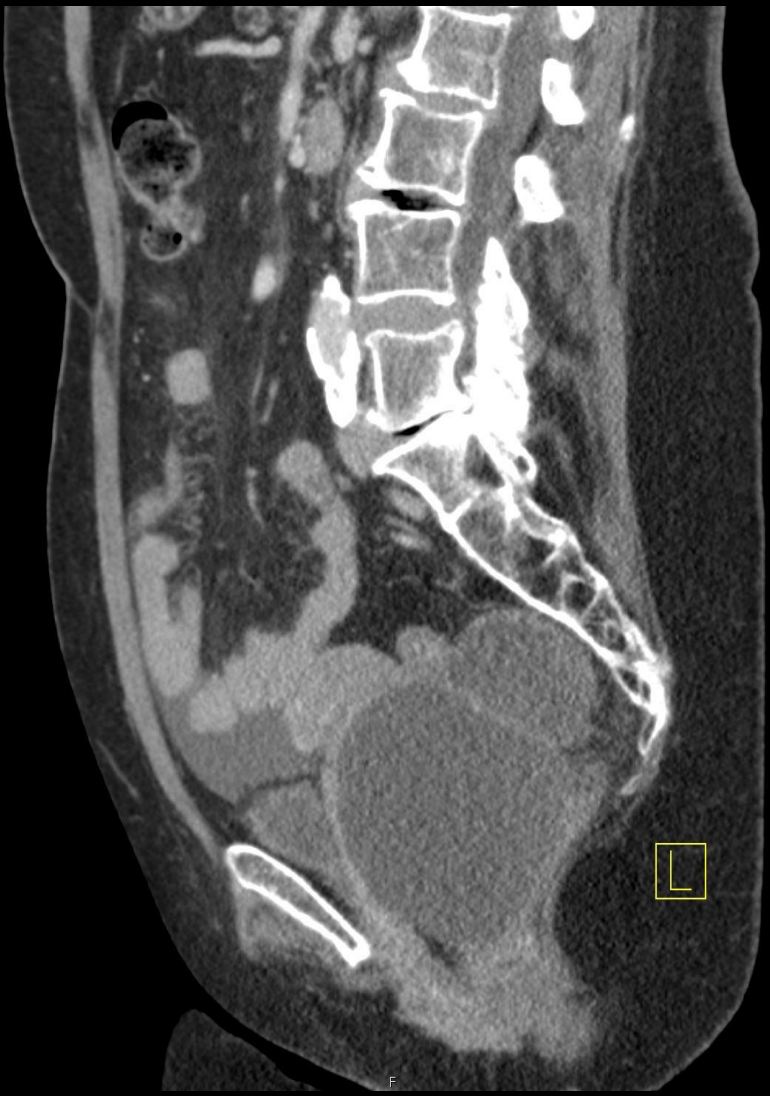ACR Appropriateness Criteria

Variant 7: Adnexal mass, highly suspicious for malignancy, no acute symptoms. Premenopausal and postmenopausal. Initial follow-up.

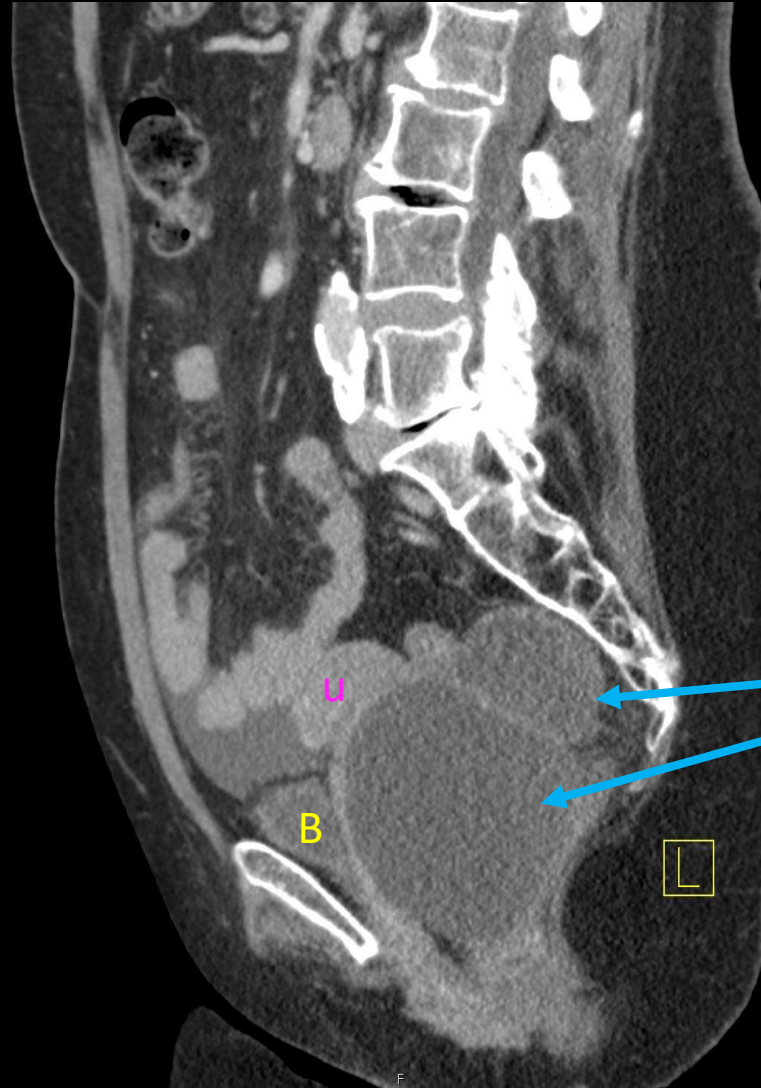
| Procedure | Appropriateness Category | Relative Radiation Level |
|--|-----------------------------------|--------------------------|
| CT abdomen and pelvis with IV contrast | Usually Appropriate | ☢☢☢ |
| MRI pelvis without and with IV contrast | Usually Appropriate | ○ |
| US pelvis transabdominal | May Be Appropriate | ○ |
| US pelvis transvaginal | May Be Appropriate | ○ |
| CT pelvis with IV contrast | May Be Appropriate (Disagreement) | ☢☢☢ |
| CT pelvis without and with IV contrast | May Be Appropriate (Disagreement) | ☢☢☢☢ |
| FDG-PET/CT skull base to mid-thigh | May Be Appropriate | ☢☢☢☢ |
| MRI pelvis without IV contrast | May Be Appropriate | ○ |
| US duplex doppler pelvis | May Be Appropriate (Disagreement) | ○ |
| CT abdomen and pelvis without IV contrast | May Be Appropriate | ☢☢☢ |
| CT abdomen and pelvis without and with IV contrast | Usually Not Appropriate | ☢☢☢☢ |
| CT pelvis without IV contrast | Usually Not Appropriate | ☢☢☢ |

Ordered by
OB/GYN after the
aborted LEEP
procedure

CT ABD/Pelvis- Sagittal View

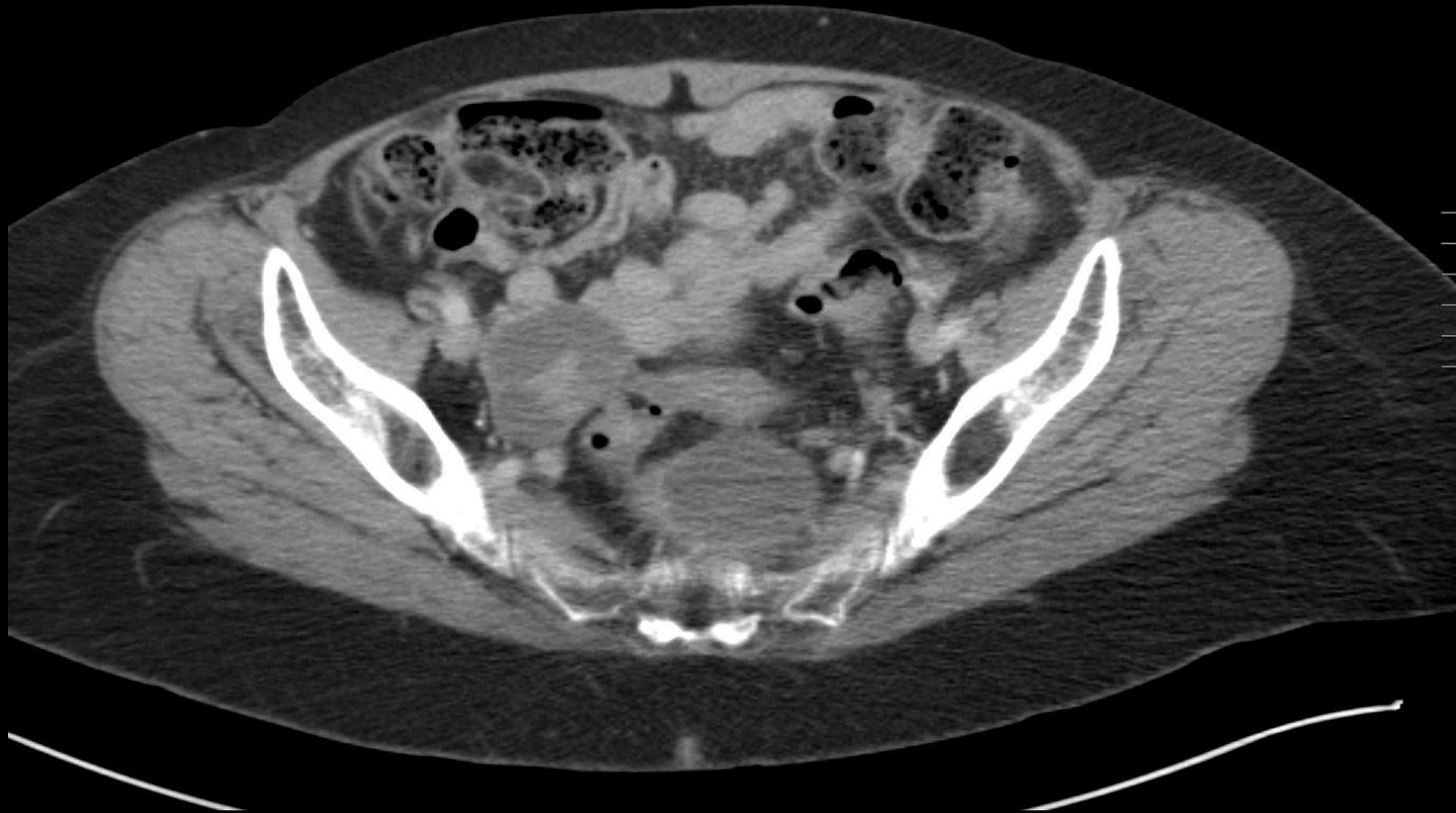

CT ABD/Pelvis-Sagittal View Findings



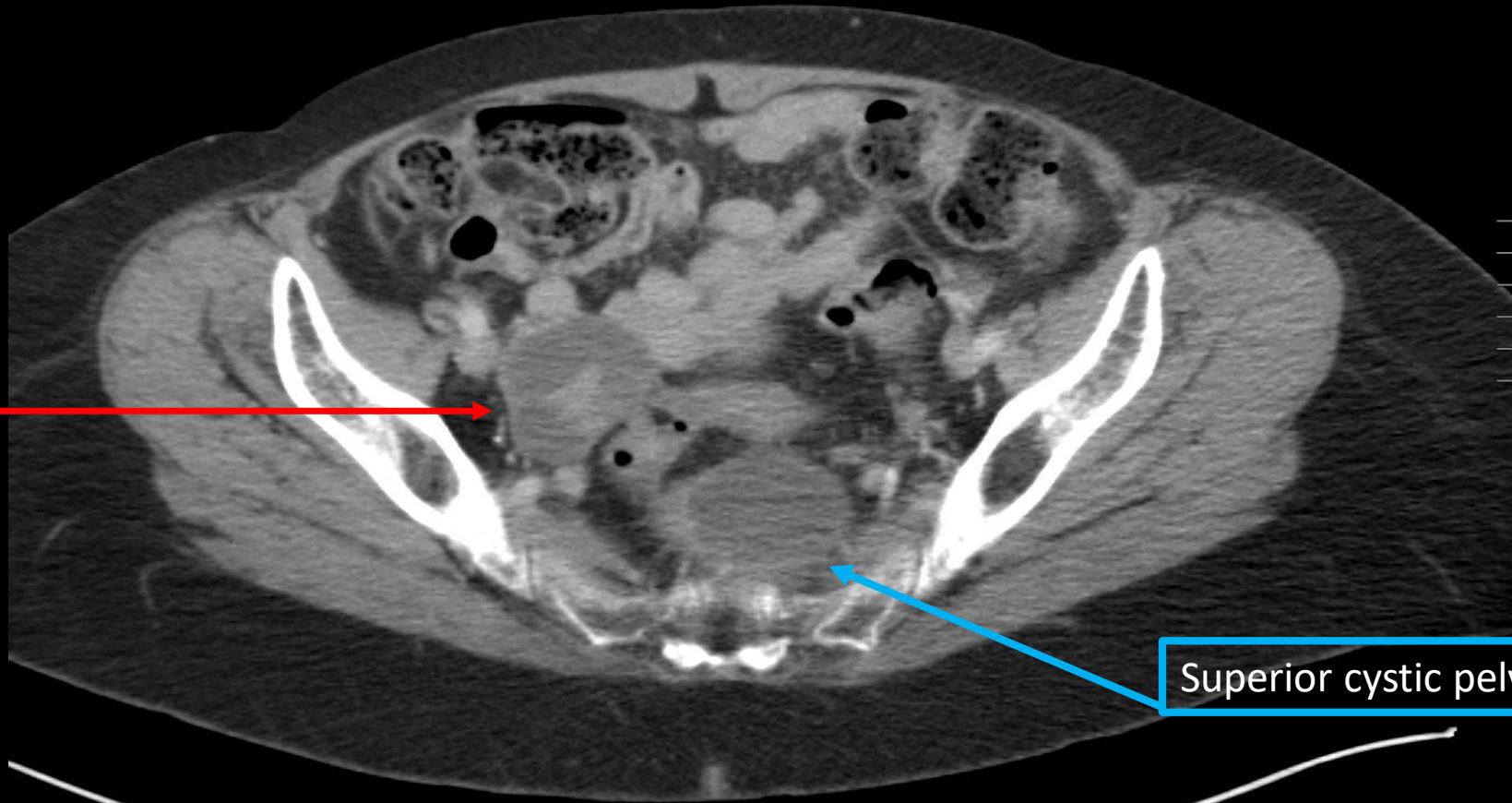
Large cystic masses

CT ABD/Pelvis-Axial View



CT ABD/Pelvis-Axial View Findings

Solid and
cystic right
ovarian mass



Superior cystic pelvic mass

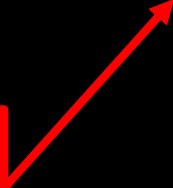
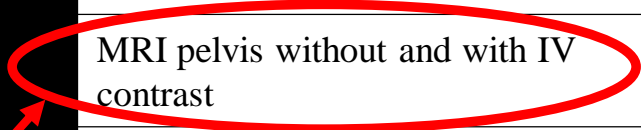
Next Step?

ACR Appropriateness Criteria

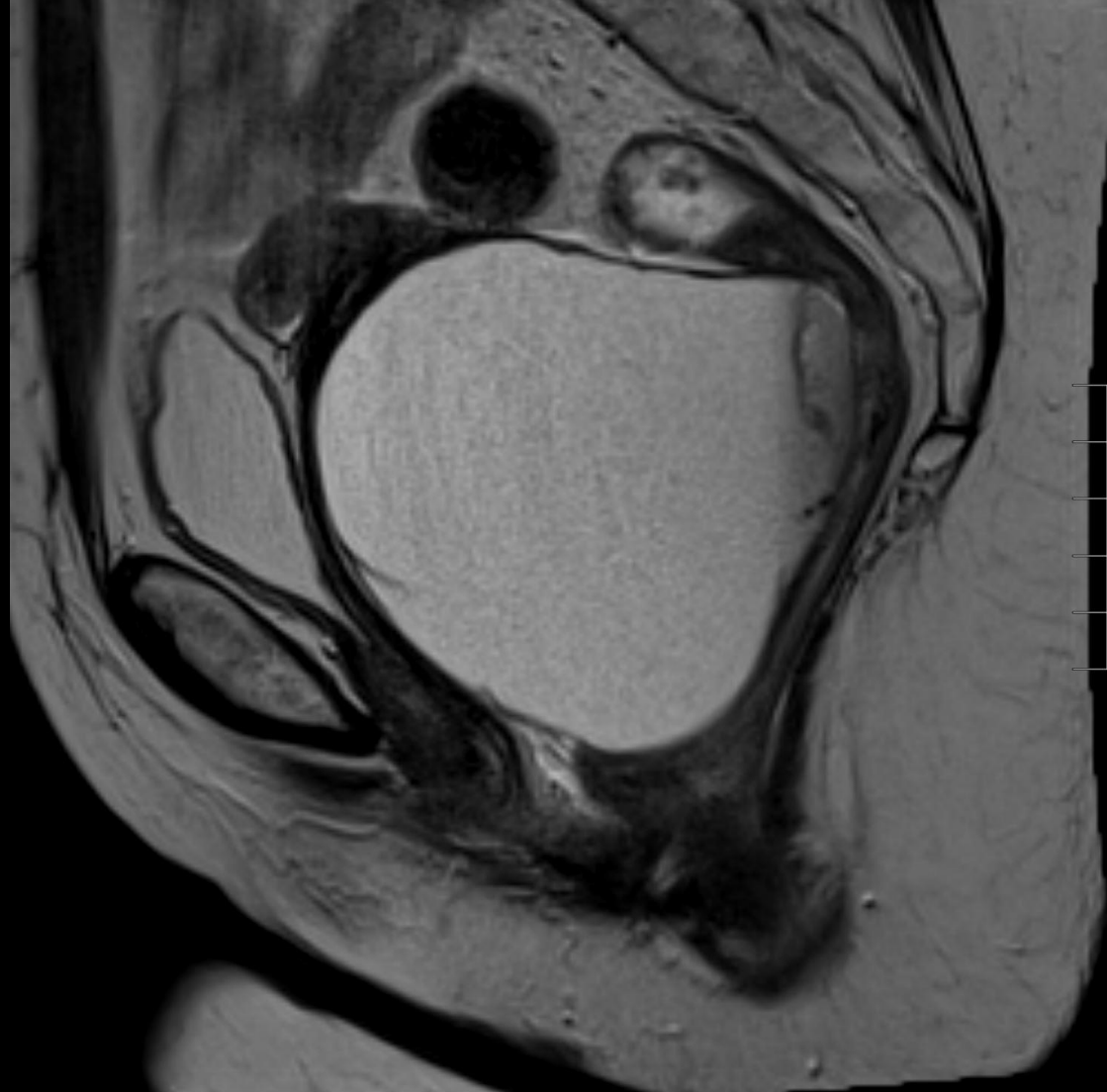
Variant 7: Adnexal mass, highly suspicious for malignancy, no acute symptoms. Premenopausal and postmenopausal. Initial follow-up.

| Procedure | Appropriateness Category | Relative Radiation Level |
|--|-----------------------------------|--------------------------|
| CT abdomen and pelvis with IV contrast | Usually Appropriate | ☢☢☢ |
| MRI pelvis without and with IV contrast | Usually Appropriate | ○ |
| US pelvis transabdominal | May Be Appropriate | ○ |
| US pelvis transvaginal | May Be Appropriate | ○ |
| CT pelvis with IV contrast | May Be Appropriate (Disagreement) | ☢☢☢ |
| CT pelvis without and with IV contrast | May Be Appropriate (Disagreement) | ☢☢☢☢ |
| FDG-PET/CT skull base to mid-thigh | May Be Appropriate | ☢☢☢☢ |
| MRI pelvis without IV contrast | May Be Appropriate | ○ |
| US duplex doppler pelvis | May Be Appropriate (Disagreement) | ○ |
| CT abdomen and pelvis without IV contrast | May Be Appropriate | ☢☢☢ |
| CT abdomen and pelvis without and with IV contrast | Usually Not Appropriate | ☢☢☢☢ |
| CT pelvis without IV contrast | Usually Not Appropriate | ☢☢☢ |

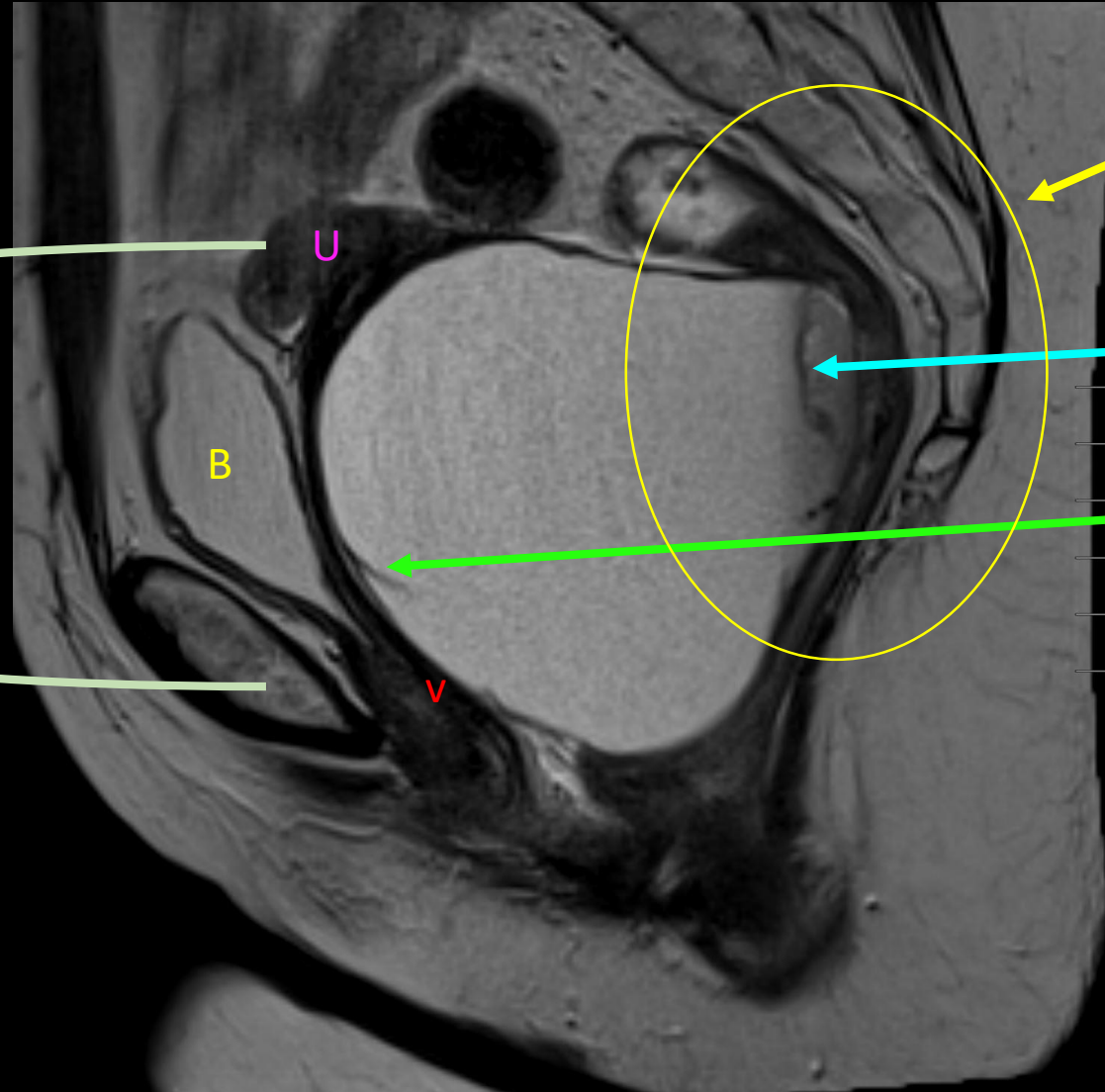
Ordered by consulted colorectal surgeon for further evaluation of masses.



MRI ABD/Pelvis- Sagittal T2 View



MRI ABD/Pelvis- Sagittal T2 View



Superior displacement of the uterus. Anterior displacement of the bladder, and vagina

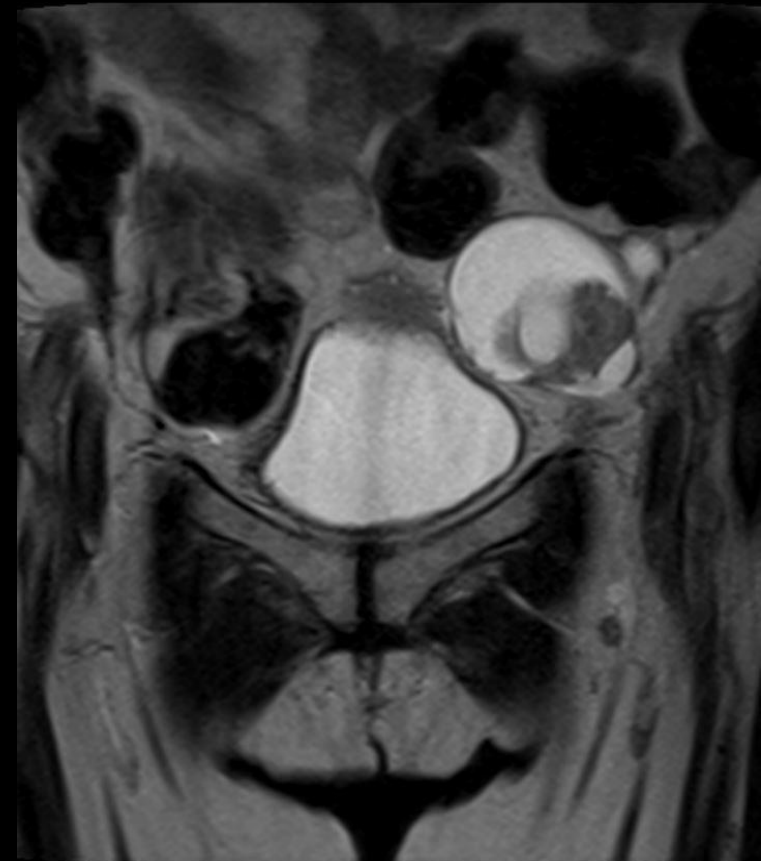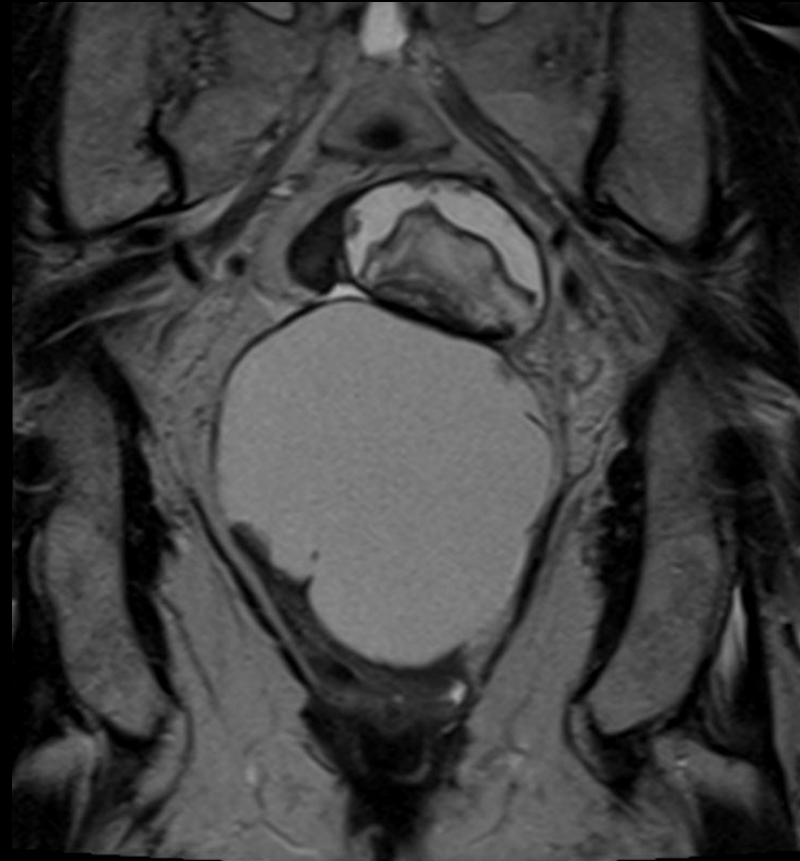
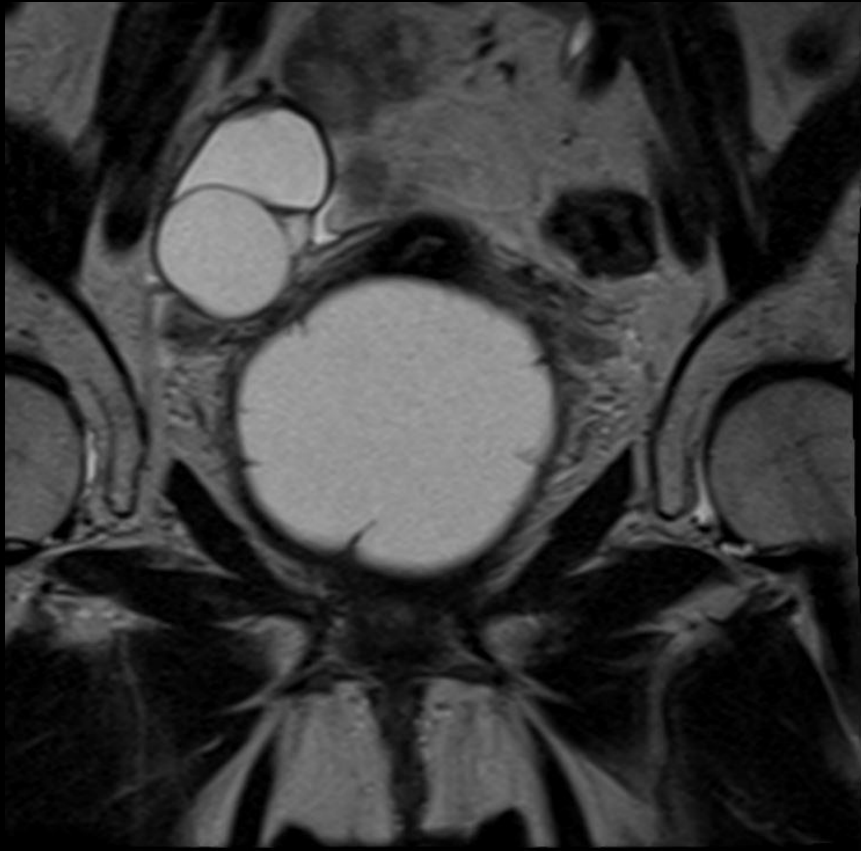
Mass effect on rectum and sigmoid colon. Posterior displacement of the rectum which is stretched over the pelvic mass.

Solid component that may be invading into the rectum

Septation

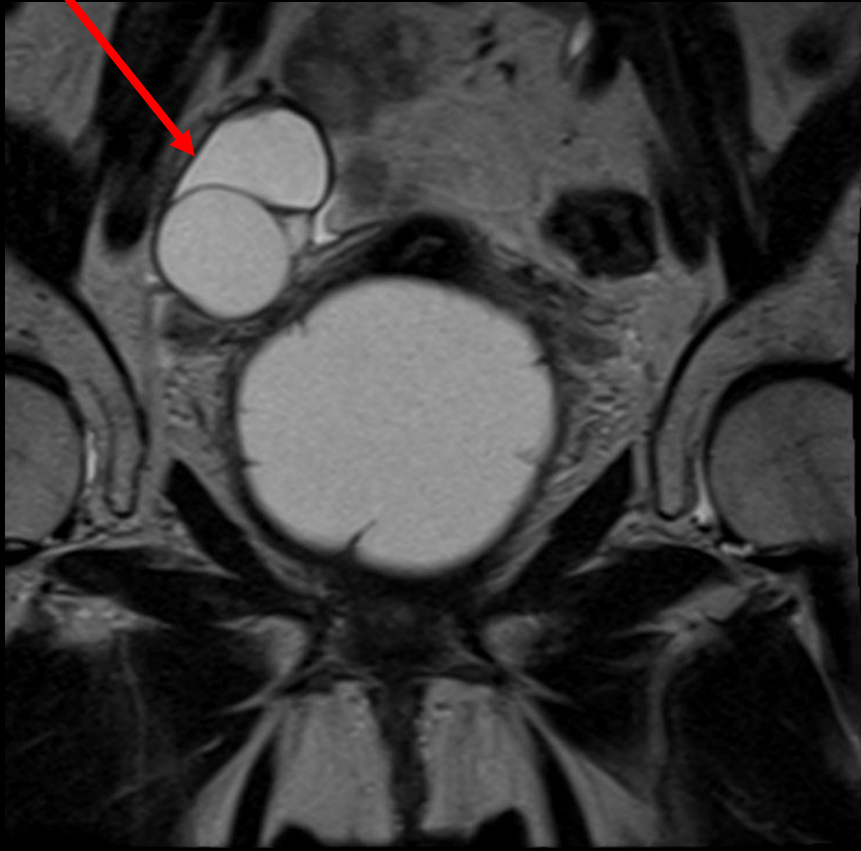
Patient mentioned in presurgical interview that she had noticed some changes in the caliber of her stool, as well as a feeling of incomplete urinary voiding in the morning.

MRI ABD/Pelvis- Coronal T2 View

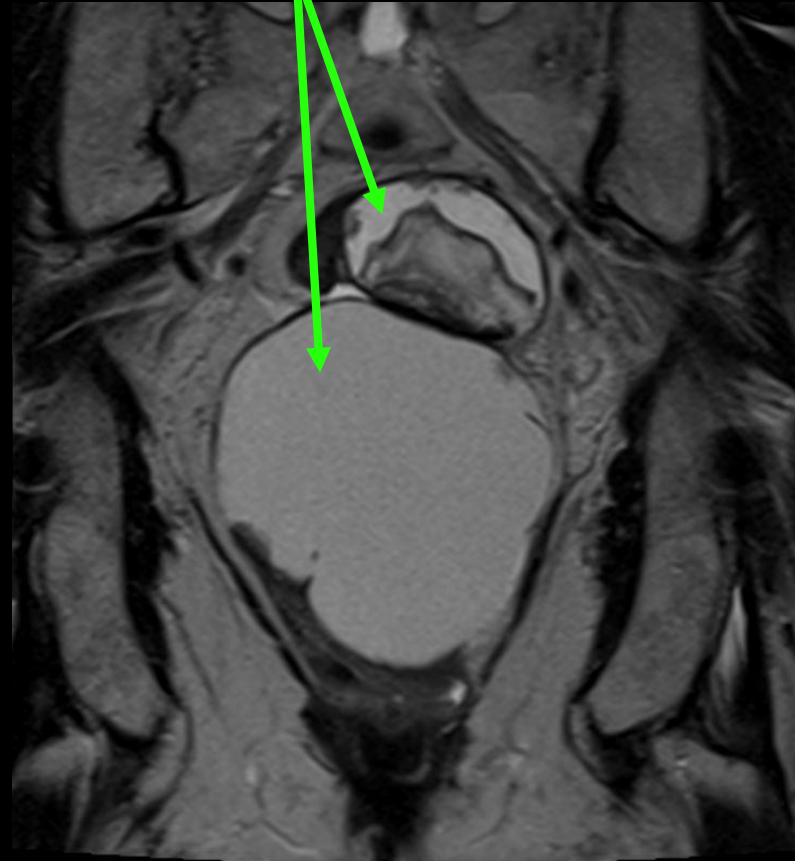


MRI ABD/Pelvis- Coronal T2 View Findings

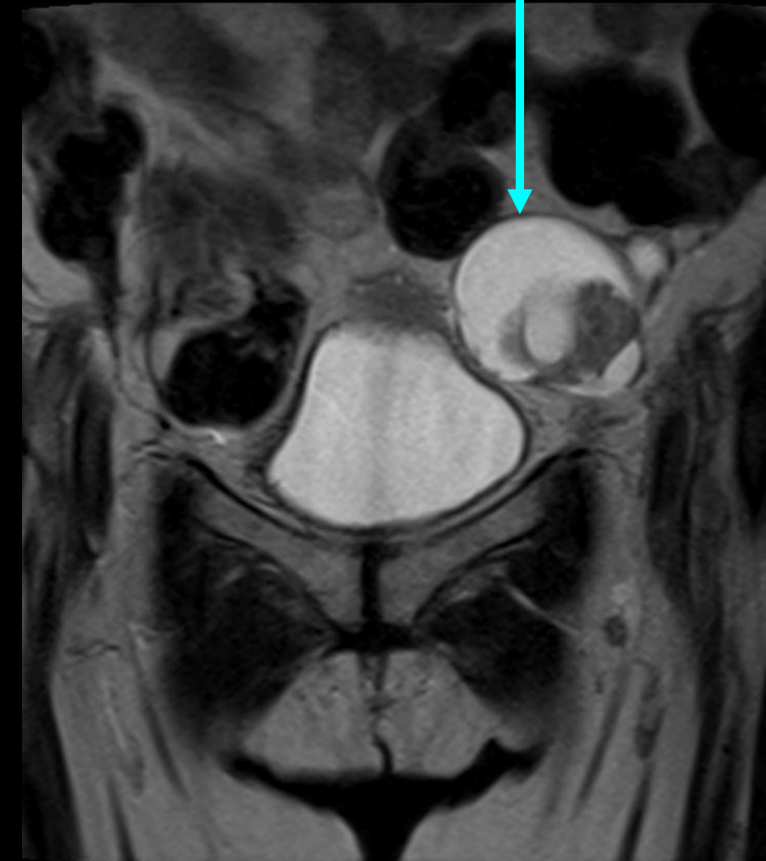
Multiloculated right ovarian mass



Two central masses with both solid and cystic components



Left ovarian mass showing cystic and solid components



Differential Diagnosis Based on Imaging

1. Ovarian malignancy
2. Gastrointestinal malignancy with metastases
3. Lymphoma
4. Sarcoma originating from the ovaries

Next Step?

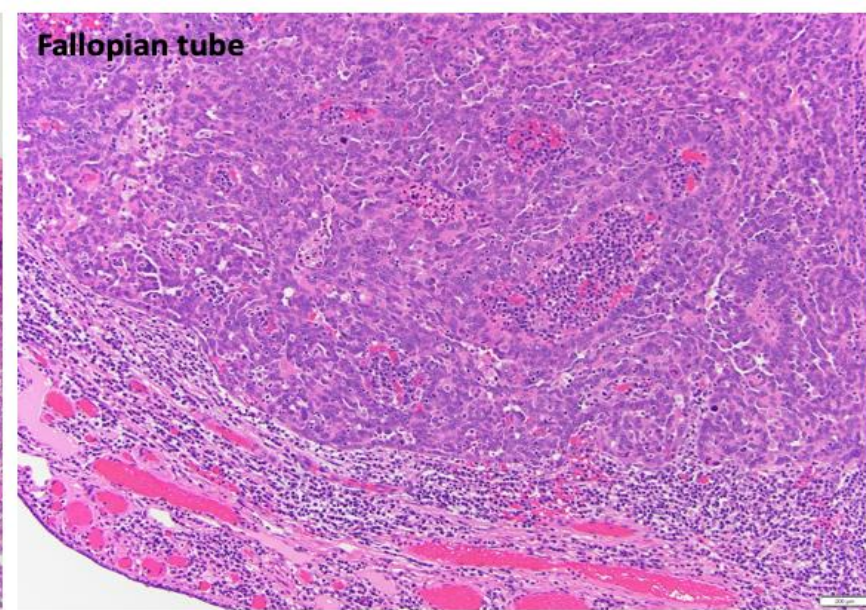
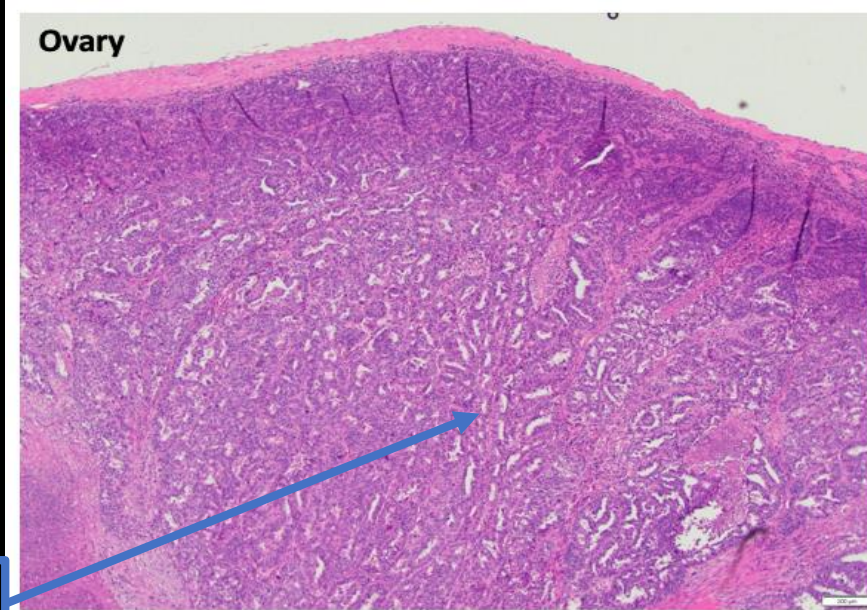
Exploratory Laparotomy with Tumor Reduction, TAH, BSO, Omentectomy, Posterior Vaginectomy, and Partial Colectomy

Frozen pathology sent during case:

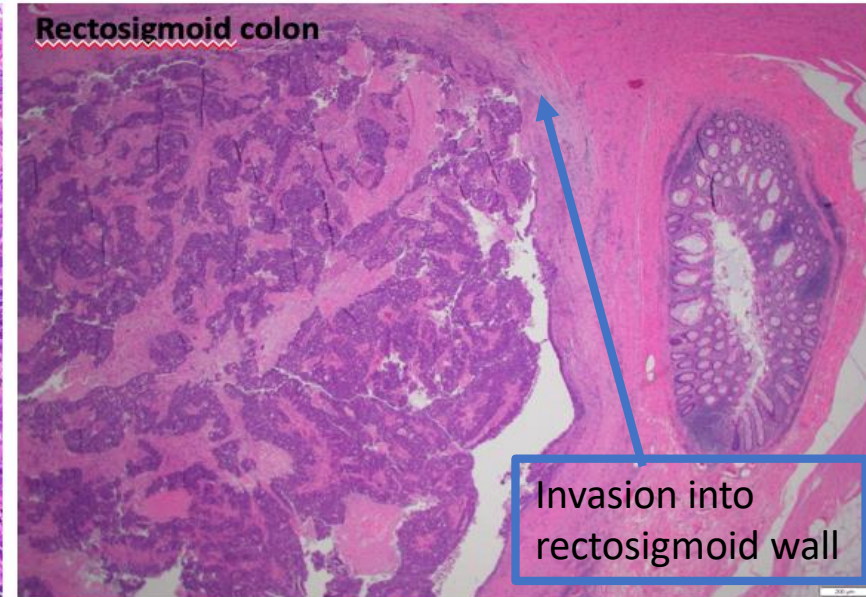
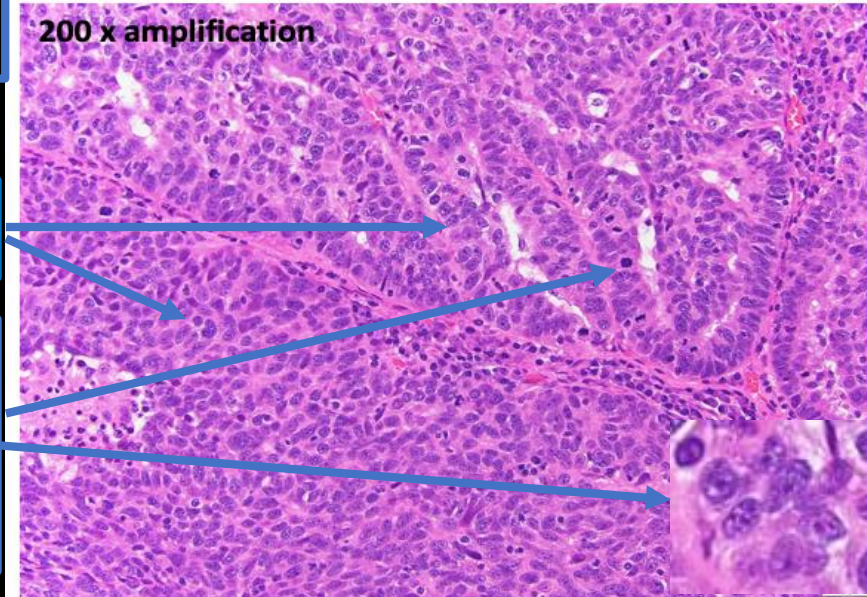
- Poorly differentiated carcinoma of gynecological origin. No sarcomatous component.

Final surgical pathology:

- Right and left ovaries and right fallopian tube with high grade serous carcinoma
- Multiple foci of high grade serous carcinoma involving the wall of the rectosigmoid colon

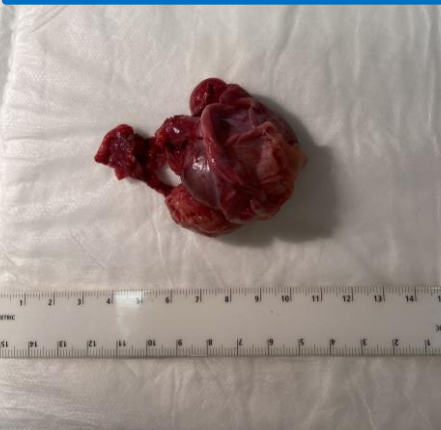

Wide spread invasion of underlying stroma



Invasion into rectosigmoid wall

Left Ovary and Uterine tube



Papillary and solid organization

Marked nuclear atypia: hyperchromic nuclei, nuclear pleomorphism, and mitotic figures

Final Diagnosis After Surgical Pathology

Stage IIB high grade serous ovarian carcinoma

Ovarian Cancer

- Ovarian Cancer is the 5th most common female cancer in the United States, 2nd most common gynecological cancer in the United States, and is the leading cause of death from gynecologic cancer in the United States
- Types of ovarian cancer: epithelial carcinomas, germ cell tumors, sex chord stromal tumors, and non-specific mesenchymal
 - About 80-85% are epithelial carcinomas:
 - Serous, mucinous, endometrioid, undifferentiated, and clear cell
 - High grade serous carcinoma makes up over 70% of all malignant epithelial carcinomas.
- Risk Factors for epithelial carcinomas:
 - Late age at menopause
 - Increasing age
 - Family history of ovarian, breast, or bowel cancer (BRACA 1&2, Lynch Syndrome)
 - 15-20% of women with high grade serous carcinoma have a hereditary disposition (BRACA 1 and 2 most commonly)
 - Nulliparous women or women with long periods of ovulation without pregnancy
- Protective Factors:
 - Use of OCPs
 - Tubal ligation/hysterectomy
 - Ovarian cancer is thought to have one of two origins: the fallopian tubes or ovarian cortical inclusion cysts. Origination from the fallopian tubes could explain why tubal ligation or salpingectomy is protective against ovarian cancer.
 - It is very likely that the origin in this case could have been the fallopian tube, as the right fallopian tube histology revealed high grade serous carcinoma

Signs and Symptoms

- Non-specific and vague, and do not tend to present until later stage disease
 - Abdominal pain and bloating
 - Compressive symptoms
 - Increased urinary frequency or urgency
 - Constipation
 - Changes in bowel movement caliber
 - Pelvic pain
 - Early satiety
 - Acute symptoms:
 - ascites
 - respiratory symptoms due to malignant pleural effusion
 - Bowel obstruction
 - Rarely ovarian torsion, rupture, or intracystic hemorrhage
- Vaginal or rectal exam usually reveals a solid, irregular, fixed, pelvic mass

After the mass was found the patient did admit to some abdominal distension and nausea as well as the compressive symptoms mentioned earlier

Screening and Prevention

- General population screening is not possible due to the lack of sensitivity and specificity of CA-125 tumor marker and TVUS for identifying cancer.
 - CA-125 becomes distorted in premenopausal women due to an association with endometriosis, PID, and uterine fibroids
- The American College of Obstetricians and Gynecologists (ACOG) recommends opportunistic bilateral salpingectomy for non-genetically predisposed women who want to reduce their risk of ovarian cancer.
- Special populations:
 - Patients with a high-risk family history for hereditary syndromes (BRACA-1, BRACA-2, Lynch syndrome etc.) should have genetic counseling and screening to guide preventative interventions.
 - Patients with hereditary disposition are encouraged to get a bilateral salpingo-oophorectomy (BSO) once childbearing is complete.

Role of CT and MRI in Ovarian Cancer

- Imaging is done preoperatively in order to assist the physician in deciding if the cancer is resectable, debulkable, or if the patient may need neoadjuvant therapy first.
- CT imaging is used to delineate the extent of intra-abdominal disease
 - Current predictive scores for successful cytoreduction in advanced ovarian cancer using CT findings in combination with functional status and other clinical factors are not yet universal due to their limitation in generalizability across cohorts other than the ones in which they were developed.
- MRI is used to further characterize the tumor, due to its superior ability to visualize soft tissue. This is especially useful when looking at local invasion.
- Criteria for unresectable tumors include:
 - Diffuse and/or deep infiltration of the small bowel mesentery
 - Diffuse carcinomatosis involving the stomach and/or large parts of the small or large bowel
 - Infiltration of the duodenum and/or parts of the pancreas (not limited to the tail)
 - Involvement of the large vessels of the hepatoduodenal ligament, celiac trunk, or behind the porta hepatis
 - Involvement of the liver parenchyma
 - Lung metastases
 - Lymph node metastases in axilla or mediastinum

Staging and Treatment

- Ovarian cancer is staged using the FIGO classification system, which is a surgical and pathological staging system. Below are the broad overarching stages, each of which have several subtypes.
 - **Stage I:** Confined to the ovaries or fallopian tubes
 - **Stage II:** Tumor involves 1 or both ovaries or fallopian tubes with pelvic extension (below pelvic brim) or peritoneal cancer
 - **Stage III:** Tumor involves 1 or both ovaries or fallopian tubes, or peritoneal cancer, with cytologically or histologically confirmed spread to the peritoneum outside the pelvis and/or metastasis to the retroperitoneal lymph nodes
 - **Stage IV:** Distant metastases excluding the peritoneum
- Initial treatment depends on the stage, but the ultimate goal is always surgical intervention.

Case Discussion Wrap Up

- This patient had FIGO stage IIB high grade serous ovarian carcinoma. IIB is defined as having one or both ovaries or fallopian tubes involved as well as extension into other pelvic intraperitoneal tissues below the pelvic brim.
 - She had bilateral ovarian involvement, and right fallopian tube involvement as well as intraperitoneal involvement including the left parametria, wall of the sigmoid colon, and rectovaginal soft tissue.
- She had a successful debulking surgery with partial colectomy, and is waiting for her colostomy reversal.
- During follow up she will be sent for genetic testing, and adjuvant therapy.

References

- Atri A, Alabusi A, Reinhold C, Akin E, Benson CB, et al. ACR Appropriateness Criteria® Clinically Suspected Adnexal Mass, No Acute Symptoms. Available at <<https://acsearch.acr.org/docs/69466/Narrative/>>. American College of Radiology. Accessed <07/14/2020>
- J., Hacker, Neville F.; Gambone, Joseph C.; Hobel, C. *Hacker & Moore's Essentials of Obstetrics and Gynecology*. Elsevier Limited (UK), 2015-10-01T00:00:00.000+00:00. [VitalSource Bookshelf].
- Aster, Vinay Kumar, Abul Abbas, J. *Robbins & Cotran Pathologic Basis of Disease*. Elsevier Health Sciences (US). [VitalSource Bookshelf].
- Chen, LM, Berek JS. Epithelial Carcinoma of the Ovary, Fallopian tube, and Peritoneum: incidence and risk factors. In: UpToDate, Post, TW (Ed), UpToDate, Waltham, MA, 2020.
- Lheureux, S., Braunstein, M. and Oza, A.M. (2019), Epithelial ovarian cancer: Evolution of management in the era of precision medicine. *CA A Cancer J Clin*, 69: 280-304. doi:[10.3322/caac.21559](https://doi.org/10.3322/caac.21559)
- Berek, J.S., Kehoe, S.T., Kumar, L. and Friedlander, M. (2018), Cancer of the ovary, fallopian tube, and peritoneum. *Int J Gynecol Obstet*, 143: 59-78. doi:[10.1002/ijgo.12614](https://doi.org/10.1002/ijgo.12614)
- Konstantinopoulos P.A, Bristow R.E, Patient selection and approach to neoadjuvant chemotherapy for newly diagnosed advanced ovarian cancer. In: UpToDate, Post, TW (Ed), UpToDate, Waltham, MA, 2020.
- Axtell AE, Lee MH, Bristow RE, Dowdy SC, Cliby WA, Raman S, Weaver JP, Gabbay M, Ngo M, Lentz S, Cass I, Li AJ, Karlan BY, Holschneider CH. Multi-institutional reciprocal validation study of computed tomography predictors of suboptimal primary cytoreduction in patients with advanced ovarian cancer. *J Clin Oncol*. 2007 Feb 1;25(4):384-9. doi: 10.1200/JCO.2006.07.7800. PMID: 17264334.
- Bristow, R.E., Duska, L.R., Lambrou, N.C., Fishman, E.K., O'Neill, M.J., Trimble, E.L. and Montz, F.J. (2000), A model for predicting surgical outcome in patients with advanced ovarian carcinoma using computed tomography. *Cancer*, 89: 1532-1540. doi:[10.1002/1097-0142\(20001001\)89:7<1532::AID-CNCR17>3.0.CO;2-A](https://doi.org/10.1002/1097-0142(20001001)89:7<1532::AID-CNCR17>3.0.CO;2-A)