

# AMSER Case of the Month: March 2020

32 year-old male with chronic lower back pain

Chad Hinkle MS4, Cooper Medical School of Rowan University



Todd Siegal MD, Pauline Germaine DO  
Cooper University Hospital



# Patient Presentation

- HPI: 32 year-old incarcerated male presented with 3 months of intermittent fevers, night sweats, right hip numbness and back pain radiating to the right groin.
- PMH: prior IV drug use, HIV, hepatitis C, infective endocarditis
- PSH: splenectomy
- Vitals: BP 157/106, HR 78, Temp 97.8 °F (36.6 °C), RR 20
- Physical Exam: Tenderness to palpation over the lumbar spine at midline and in right lower back. No deformities or erythema.

# Pertinent Labs

- CBC
  - WBC 13.3 ↑
  - Hgb 9.8 ↓
  - Platelets 478 ↑
- CRP 0.53 ↑ , ESR 58 ↑
- Lactate - normal (0.7)
- Urine Drug Screen – negative
- Blood culture – negative

What Imaging Should We Order?

# Select the applicable ACR Appropriateness Criteria

**Clinical Condition:** Low Back Pain

**Variant 3:** Acute, subacute, or chronic low back pain or radiculopathy. One or more of the following: suspicion of cancer, infection, or immunosuppression.

Radiologic Procedure	Rating	Comments	RRL*
MRI lumbar spine without and with IV contrast	8	Contrast is useful for neoplasia patients suspected of epidural or intraspinal disease.	○
MRI lumbar spine without IV contrast	7	Noncontrast MRI can be sufficient if there is low risk of epidural and/or intraspinal disease.	○
CT lumbar spine with IV contrast	6	MRI is preferred. CT is useful if MRI is contraindicated or unavailable and/or for problem solving.	☼☼☼
CT lumbar spine without IV contrast	6	MRI is preferred. CT is useful if MRI is contraindicated or unavailable and/or for problem solving.	☼☼☼
X-ray lumbar spine	5		☼☼☼
Tc-99m bone scan whole body with SPECT spine	4	SPECT/CT can be useful for anatomic localization and problem solving, in particular if looking for widespread tumor burden. It is valuable when multifocal metastases are suspected.	☼☼☼
FDG-PET/CT whole body	4	MRI is preferred. This procedure can be indicated if MRI is contraindicated or nondiagnostic. It can distinguish benign versus malignant compression fractures.	☼☼☼☼
CT lumbar spine without and with IV contrast	3	MRI is preferred. This procedure can be indicated if MRI is contraindicated or nondiagnostic.	☼☼☼☼
CT myelography lumbar spine	3	MRI is preferred. This procedure can be indicated if MRI is contraindicated or nondiagnostic and can be useful for anatomic localization and problem solving.	☼☼☼☼

**Rating Scale:** 1,2,3 Usually not appropriate; 4,5,6 May be appropriate; 7,8,9 Usually appropriate

\*Relative Radiation Level

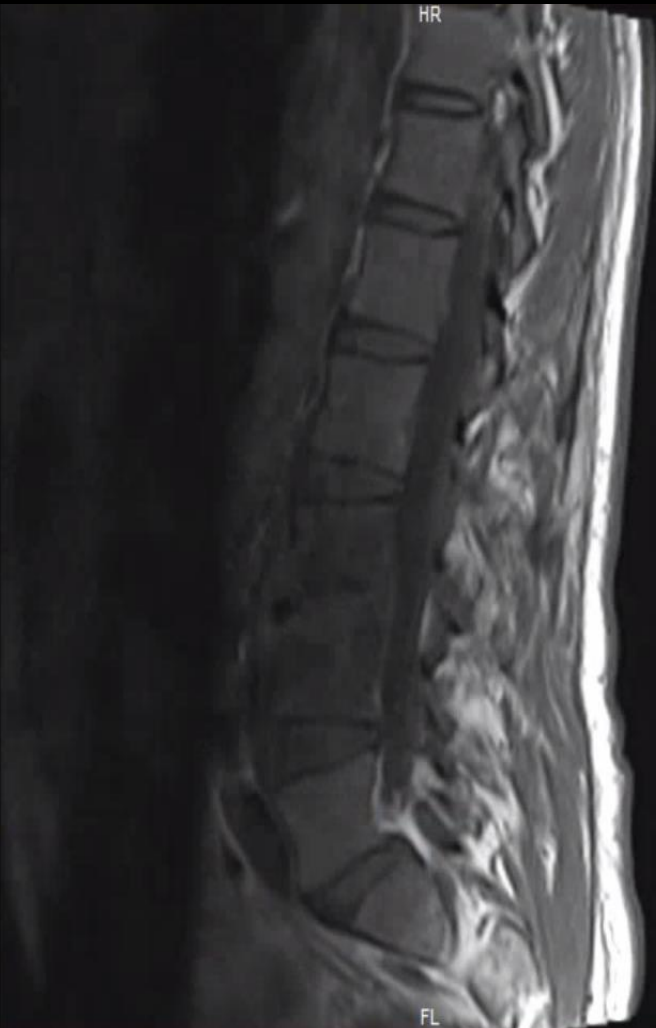These imaging modalities were ordered by the outside hospital ED.

This imaging modality was ordered by the accepting hospital ED after transfer.

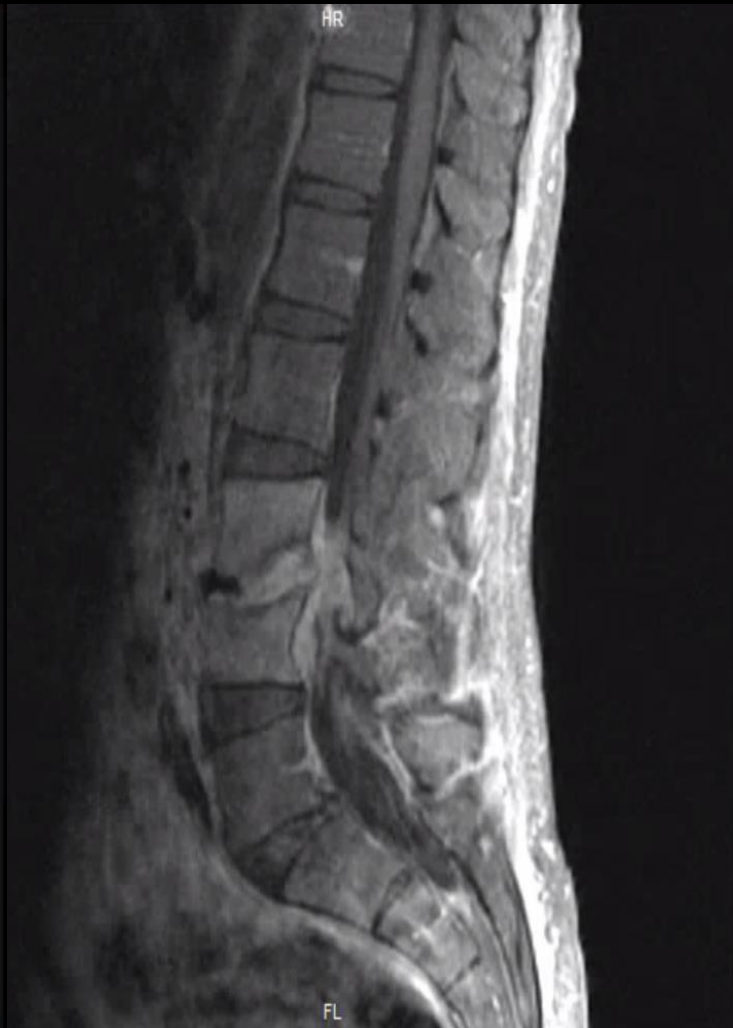

# Findings: Unlabeled

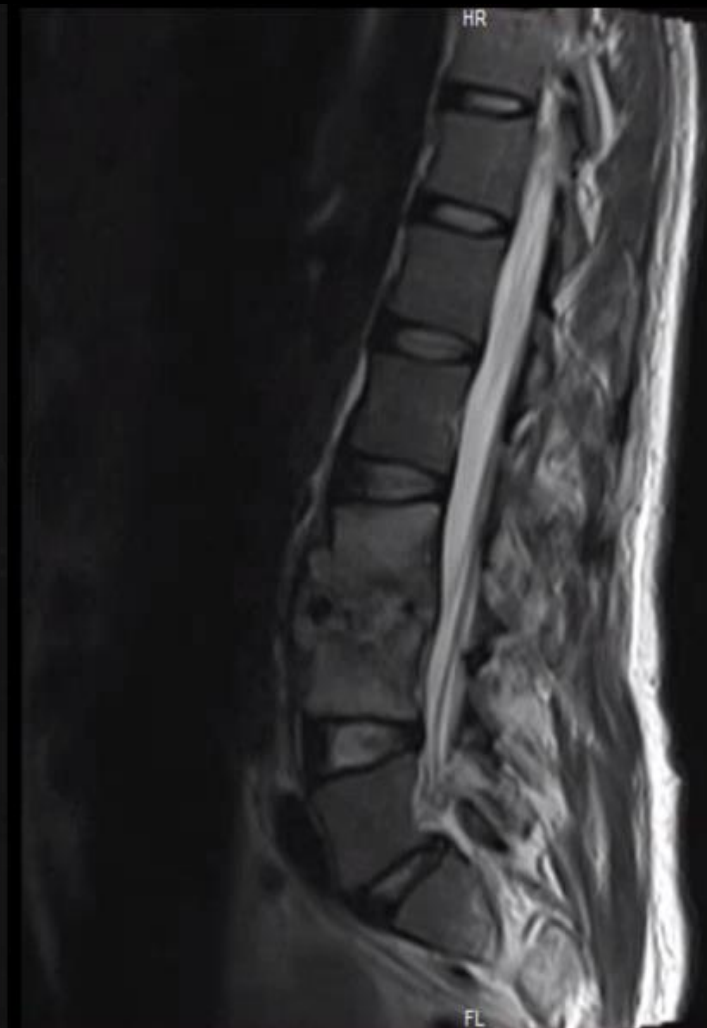Sagittal T1 pre-contrast



Sagittal T1 post-contrast

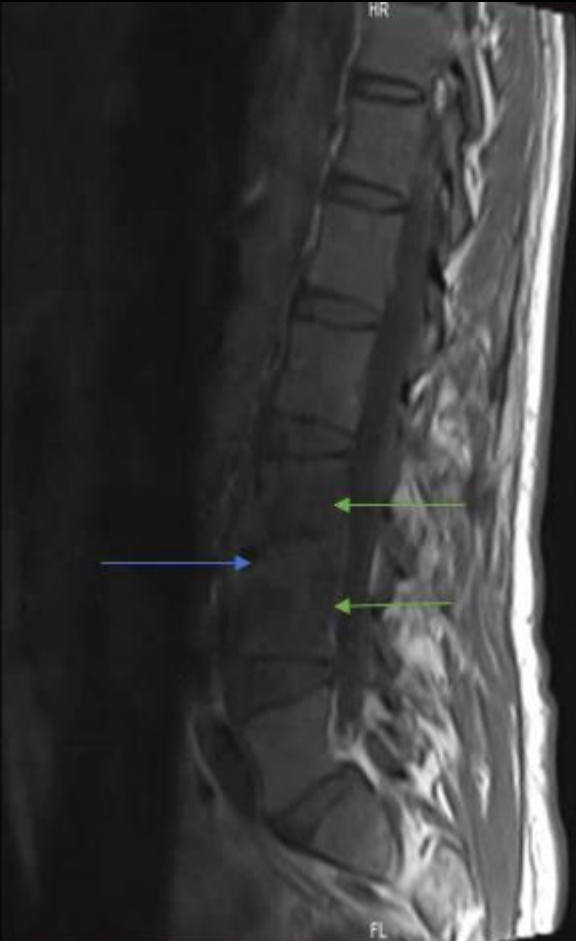


Sagittal T2

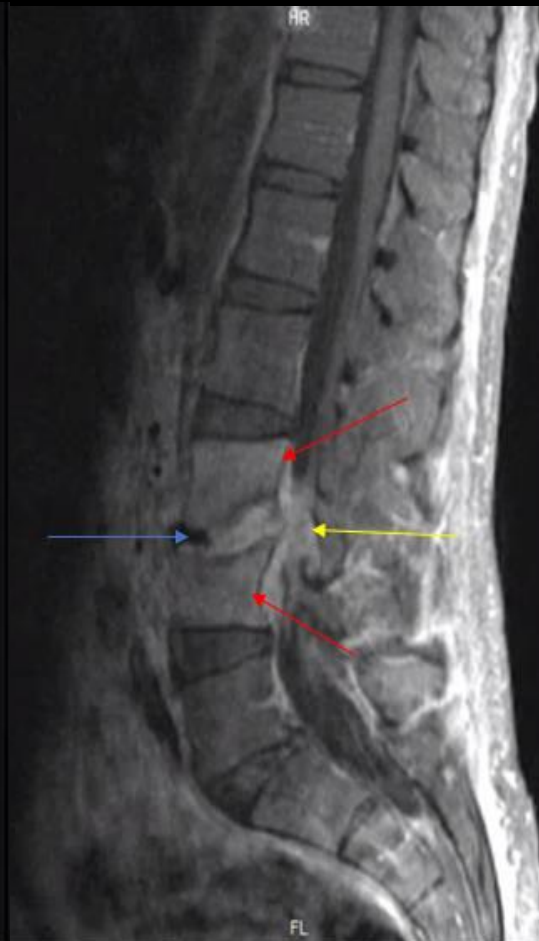

# Findings: Labeled

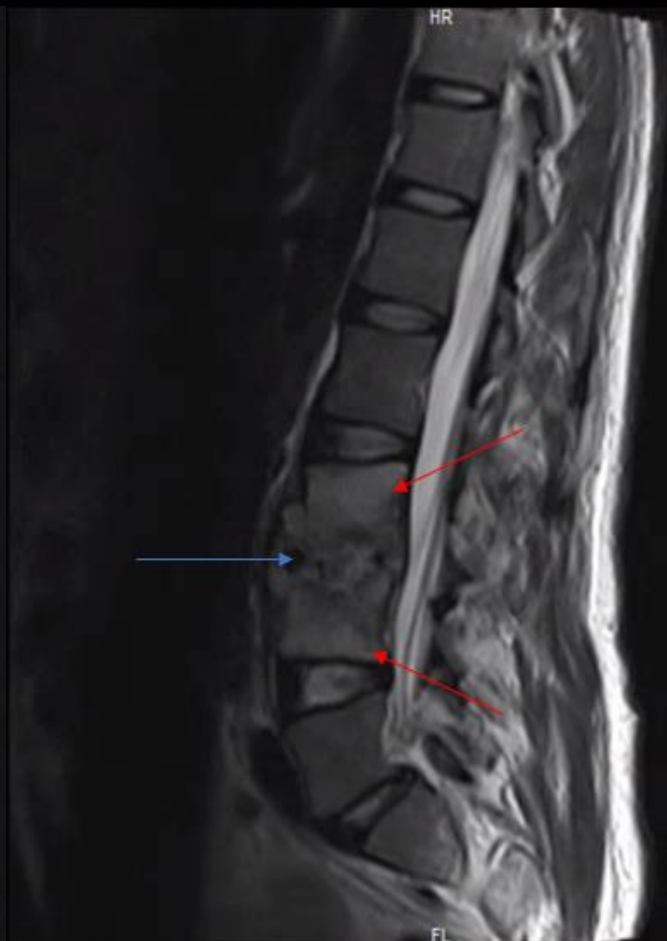Sagittal T1 pre-contrast



Sagittal T1 post-contrast



Sagittal T2 w contrast



Low T1 signal intensity in L3 and L4 vertebral bodies

Diffuse bone marrow edema and enhancement of L3 and L4 vertebral bodies (VB)

Collapse of L3 VB inferior and L4 VB superior endplates with disc space narrowing, abnormal signal and enhancement

Phlegmonous inflammatory change in ventral epidural space with thecal sac narrowing



Final Dx:

Lumbar Spine (L3-4) Osteomyelitis and Discitis



# Pyogenic Spondylitis: Etiology

- Spondylitis is osteomyelitis of the vertebral bone, which can be pyogenic (pus-forming) or non-pyogenic (granulomatous)
  - Pyogenic: *Staphylococcus sp.* > *Enterobacter sp.* > *Streptococcus sp.*
  - Non-pyogenic: TB, fungi, *brucella*, sarcoid
- Transmission tends to occur via hematogenous seeding of the vertebral bodies more often than the avascular intervertebral discs
  - Lumbar spine more commonly involved than thoracic or cervical
  - Average time of diagnosis after first symptoms is delayed: 2-6 months
- Risk factors include **IV drug use**, immunosuppression (**HIV**, **splenectomy**), diabetes

# Case Discussion: Presentation

- Clinical presentation is non-specific contributing to the delay in diagnosis
  - Diffuse back pain, fever, chills, pain to percussion, paresthesias/weakness
- Laboratory diagnosis
  - Elevated ESR and CRP during acute infection, leukocytosis (not always present)
- Treatment
  - Antibiotic treatment always guided by identification of specific pathogen
  - Parenteral antibiotic therapy for 4-6 weeks is preferred over oral

# Pyogenic Spondylitis: Imaging

- Radiographic imaging tends to have low specificity in diagnosis
  - Crucial in initial evaluation but findings not apparent until 2-8 weeks after infection
  - May show disc space narrowing and irregularity of vertebral endplates
- CT is more sensitive in detecting earlier inflammatory change
  - May demonstrate disc space narrowing, endplate irregularity, soft tissue inflammatory changes and abscess formation
- MRI is most sensitive in characterizing spondylitis and complications
  - T1: low signal in disc and vertebral bodies representing edema
  - T2: high signal in disc and vertebral bodies; hyperintensity within psoas muscle (imaging psoas sign)
  - DWI: hyperintense during acute infection; hypointense with chronic infection

# Patient Follow-Up

- Patient underwent CT-guided biopsy showing MSSA spondylitis and discitis.
- Patient was started on IV antibiotics with plan for PICC placement to receive the remaining treatment course in jail.
- Patient refused PICC placement; discharged to jail with PO antibiotics and follow-up X-rays in 4 weeks.

# References:

- Sobottke R, Seifert H, et al. Current Diagnosis and Treatment of Spondylodiscitis. *Dtsch Arztebl Int.* 2008; 105(10): 181-187.
- Frel M, Bialecki J, et al. Magnetic Resonance Imaging in Differential Diagnosis of Pyogenic Spondylodiscitis and Tuberculous Spondylodiscitis. *Pol J Radiol.* 2017; 82: 71-87.
- Murphy A, Jin TY, et al. Pyogenic spondylitis. Radiopaedia.org
- Bell D, Gaillard F, et al. Spondylodiskitis. Radiopaedia.org
- Mavrogenis A, Megaloikonomos P, et al. Spondylodiscitis revisited. *EFORT Open Reviews.* 2017; 2(11): 1-15.
- ACR Appropriateness Criteria for low back pain. American College of Radiology. <https://acsearch.acr.org/docs/69483/Narrative/>